



PATIENT PRESENTING CLINICAL SIGNS

Lennox Salvage Started coughing and not eating about 2 days prior to presentation. Lethargic
Abnormal PE/Chem/CBC/UA Results: Fever 103.5 QAR Deep cough in exam room

SPECIES RADIOGRAPHIC STUDY OF THE THORAX

Canine Radiographs of the thorax in three imaging planes are provided for review.

RADIOGRAPHIC FINDINGS

BREED The surrounding bony structures are within normal limits.

Irish Setter The extrathoracic soft tissues present homogeneous without abnormalities.

The heart is of normal size and shape, there is no evidence of cardiac chamber or vascular enlargement. The pulmonary vasculature is within normal limits.

SEX The cranial mediastinum presents the expected soft tissue opacity. The mediastinal width is less than twice the width of the vertebral column at the same level.

Male

The trachea is normal in diameter and presents the anticipated course. The luminal outline of the trachea is smooth.

AGE

5 Years, 3 Months

In the right caudal lung lobe, a roundish soft tissue opacity with a gas opaque center, measuring approximately two intercostal spaces in diameter is appreciated. The remainder of the lung parenchyma are aerated and present the expected architecture.

INTERPRETED BY

The diaphragm is well delineated with even surface and the expected mild cranial bulging of the diaphragmatic cupola.

Sebastian Schaub, DVM
Dr. med. vet. DipECVCI

RADIOGRAPHIC DIAGNOSIS

- Soft tissue mass right caudal lung lobe, possible cavitated

HOSPITAL NAME

Grove Veterinary
Clinic

INTERPRETATION OF THE FINDINGS & FURTHER RECOMMENDATIONS

The soft tissue mass in the right caudal lung lobe can present primary pulmonary neoplasm (e.g. carcinoma), granuloma or pulmonary abscess. Ultrasound guided FNA sampling of the pulmonary mass via the 8th intercostal space can be tried for further workup.

REFERRING VET

Dr. Luna

INVOICE

59678

DATE

8-14-23



PATIENT

Lennox Salvage

SPECIES

Canine

BREED

Irish Setter

SEX

Male

AGE

5 Years, 3 Months

INTERPRETED BY

Sebastian Schaub, DVM
Dr. med. vet. DipECVDI

HOSPITAL NAME

Grove Veterinary
Clinic

REFERRING VET

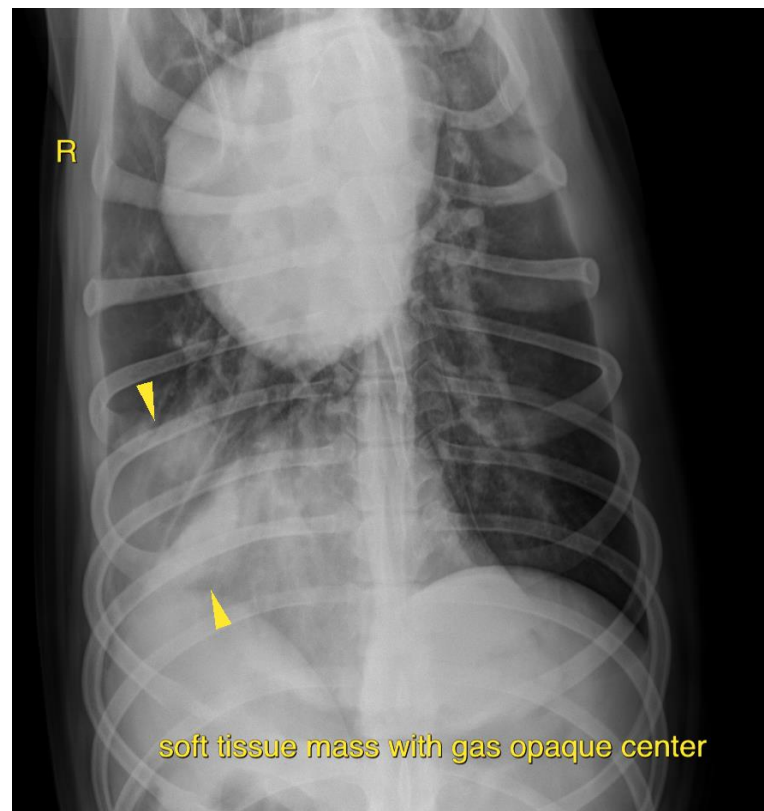
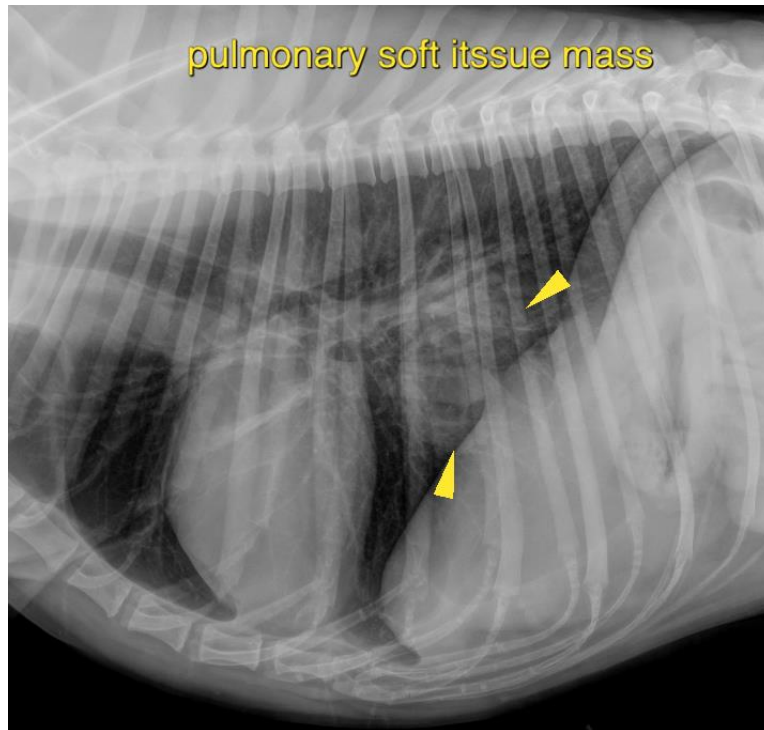
Dr. Luna

INVOICE

59678

DATE

8-14-23





PATIENT

Lennox Salvage

The information and recommendations provided are based on the images presented by the referring veterinarian/sonographer. No evaluation can be communicated regarding pathology that was not visible in the image/video clips provided.

SPECIES

Canine

Thank you for this referral. If the clinical or image interpretation does not parallel your findings or if I can be of any further assistance please contact me.

BREED

Irish Setter

Sebastian Schaub, Sebastian Schaub, DVM, Dr. med. vet. DipECVDI
info@sonopath.com

SEX

Male

AGE

5 Years, 3 Months

INTERPRETED BY

Sebastian Schaub, DVM
Dr. med. vet. DipECVDI

HOSPITAL NAME

Grove Veterinary
Clinic

REFERRING VET

Dr. Luna

INVOICE

59678

DATE

8-14-23