



**PATIENT PRESENTING CLINICAL SIGNS**

Ace Ventura has surgical plan to remove the mass from left leg, cytology of the mass shows it is lipoma however surgeon would like to know if the feature of the mass is otherwise radiographically  
Abnormal PE/Chem/CBC/UA Results: large mass in left rear leg

**SPECIES RADIOGRAPHIC STUDY OF THE RIGHT HIND LIMB**

Canine Radiographs of the right hind limb are provided for review.

**RADIOGRAPHIC FINDINGS**

**BREED**  
Doberman At the caudal aspect of the right stifle joint, an ill-defined, fat attenuating mass with an interspersed irregular soft tissue striation is appreciated. The mass is extending predominantly proximally approximately up to the level of the mid third of the diaphysis of the right femur and is measuring approximately 13 x 10 x 7 cm. The soft tissue shadow of the right popliteal lymph node is prominent.

**SEX RADIOGRAPHIC DIAGNOSIS**

Neutered

- Suspect infiltrative lipoma caudodistal aspect right thigh
- Lymphadenopathy right popliteal lymph node

**AGE INTERPRETATION OF THE FINDINGS & FURTHER RECOMMENDATIONS**

8 Years The appreciated lipoma at the caudodistal aspect of the right thigh presents an irregular soft tissue striation and ill-defined margins, rendering the odds for infiltrative lipoma high. Theoretically liposarcoma can be a differential as well. A CT study of the right hind limb is considered ideal for surgical planning.

**INTERPRETED BY**

Sebastian Schaub, DVM  
Dr. med. vet. DipECVDI

Consider FNA sampling of the right popliteal lymph node to differentiate between reactive hyperplasia or malignant infiltration.

**HOSPITAL NAME**

CJAH

**REFERRING VET**

Gabriel

**INVOICE**

59673

**DATE**

8-14-23



**PATIENT**

Ace Ventura

**SPECIES**

Canine

**BREED**

Doberman

**SEX**

Neutered

**AGE**

8 Years

**INTERPRETED BY**

Sebastian Schaub, DVM  
Dr. med. vet. DipECVDI

**HOSPITAL NAME**

CJAH

**REFERRING VET**

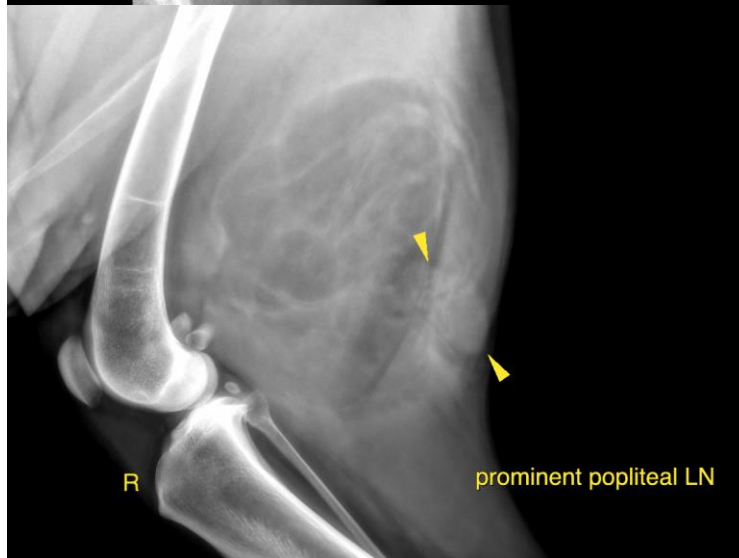
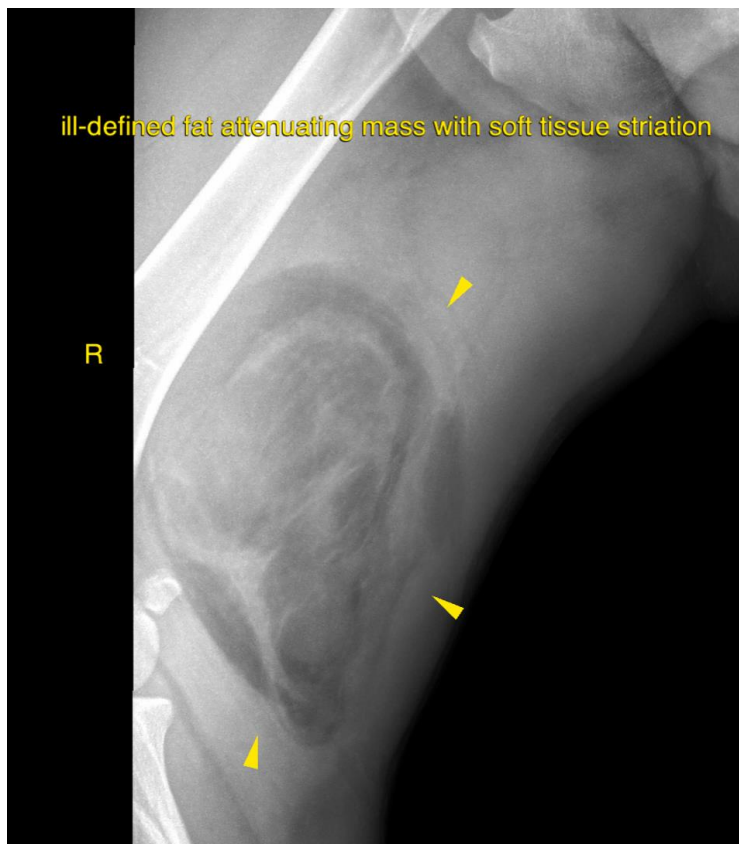
Gabriel

**INVOICE**

59673

**DATE**

8-14-23





**PATIENT** The information and recommendations provided are based on the images presented by the referring veterinarian/sonographer. No evaluation can be communicated regarding pathology that was not visible in the image/video clips provided.

Ace Ventura

Thank you for this referral. If the clinical or image interpretation does not parallel your findings or if I can be of any further assistance please contact me.

**SPECIES**

Canine **Sebastian Schaub**, Sebastian Schaub, DVM, Dr. med. vet. DipECVDI  
[info@sonopath.com](mailto:info@sonopath.com)

**BREED**

Doberman

**SEX**

Neutered

**AGE**

8 Years

**INTERPRETED BY**

Sebastian Schaub, DVM  
Dr. med. vet. DipECVDI

**HOSPITAL NAME**

CJAH

**REFERRING VET**

Gabriel

**INVOICE**

59673

**DATE**

8-14-23