



**PATIENT PRESENTING CLINICAL SIGNS**

Waldo Eisen annual exam July 28th/2022 at rdvm Incidental 8mm subQ mass found on left thorax on physical examination. Cytology supposedly revealed spindle cell proliferation and consistent with a spindle cell tumor.

**SPECIES COMPUTED TOMOGRAPHY OF THE THORAX**

Canine A pre- and post-contrast CT study of the thorax in a lung and soft tissue reconstruction is provided for review.

**BREED COMPUTED TOMOGRAPHIC FINDINGS**

Shepherd X The vertebral endplates C7/T1 and T13/L1 present moderate spondylosis formation.

In the subcutaneous tissue of the left thoracic wall, level with the 8<sup>th</sup> left rib, a well-defined, soft tissue attenuating nodule is visible, measuring 5 mm in diameter.

**SEX**

MN

The sternal, cranial mediastinal and tracheobronchial lymph nodes are small elongated with a normal short-to-long-axis-ratio is < 0.5, the attenuation and contrast enhancement pattern is uniform and considered within normal limits.

**AGE**

3 Years

The cardiovascular structures including the pulmonary vasculature are within normal limits.

The bronchial tree presents with regular branching and tapers uniformly towards the periphery as expected, the bronchial walls are thin and smooth. The bronchus-to-artery ratio is within normal limits.

**INTERPRETED BY**

Sebastian Schaub, DVM  
Dr. med. vet. DipECVDI

The lung parenchyma presents the expected architecture and attenuation behavior.

Small incidental gas pockets are seen within the esophageal lumen, there is no evidence of abnormal dilation.

**HOSPITAL NAME COMPUTED TOMOGRAPHIC DIAGNOSIS**

Animal Health  
Partners

- Non-specific subcutaneous soft tissue nodule left thoracic wall
- No evidence of pulmonary metastatic disease
- Spondylosis deformans

**REFERRING VET INTERPRETATION OF THE FINDINGS & FURTHER RECOMMENDATIONS**

Dr. Debbie Reynolds The subcutaneous nodule is not specific, complete surgical excision is considered feasible.

**INVOICE**

53454

**DATE**

8-13-22



**PATIENT**

Waldo Eisen

**SPECIES**

Canine

**BREED**

Shepherd X

**SEX**

MN

**AGE**

3 Years

**INTERPRETED BY**

Sebastian Schaub, DVM  
Dr. med. vet. DipECVDI

**HOSPITAL NAME**

Animal Health  
Partners

**REFERRING VET**

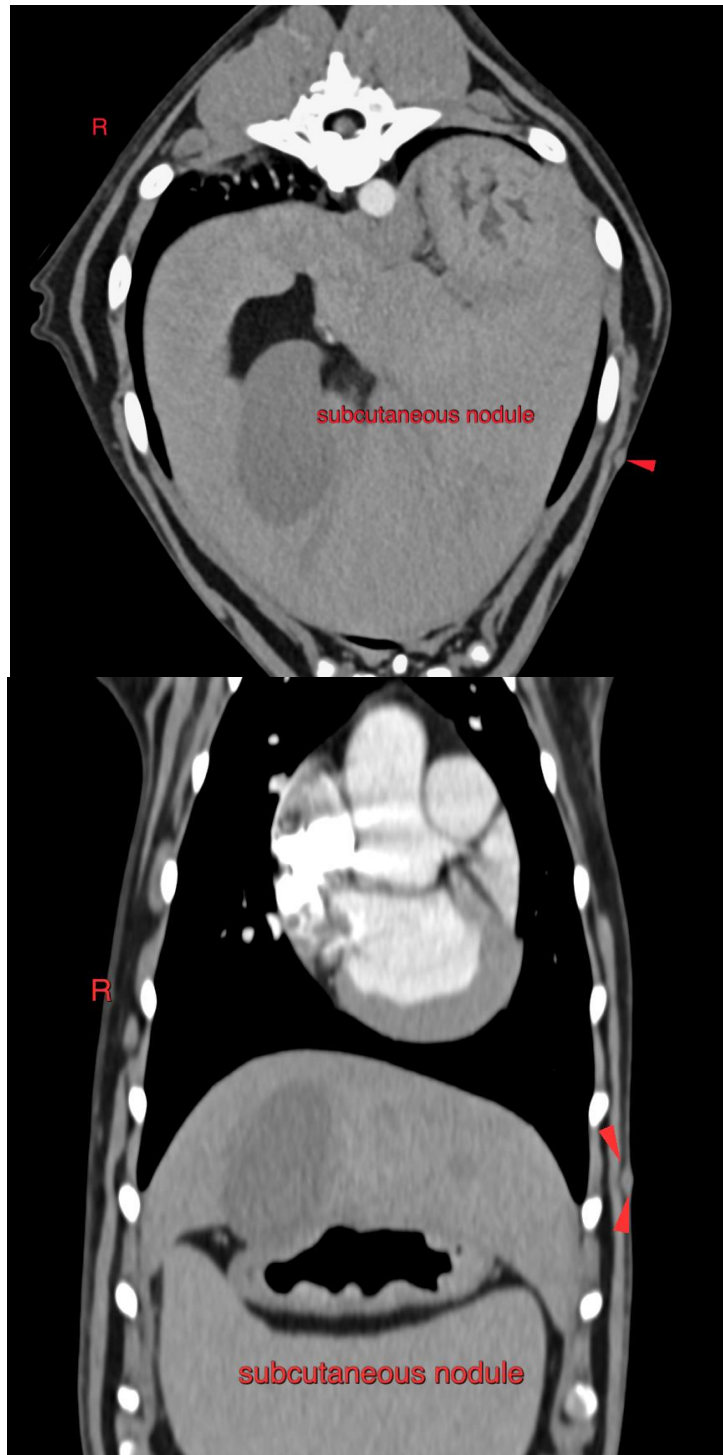
Dr. Debbie Reynolds

**INVOICE**

53454

**DATE**

8-13-22





**PATIENT**

Waldo Eisen

The information and recommendations provided are based on the images presented by the referring veterinarian/sonographer. No evaluation can be communicated regarding pathology that was not visible in the image/video clips provided.

**SPECIES**

Canine

Thank you for this referral. If the clinical or image interpretation does not parallel your findings or if I can be of any further assistance please contact me.

**BREED**

Shepherd X

**Sebastian Schaub**, Sebastian Schaub, DVM, Dr. med. vet. DipECVDI  
sebast.schaub@gmail.com

**SEX**

MN

**AGE**

3 Years

**INTERPRETED BY**

Sebastian Schaub, DVM  
Dr. med. vet. DipECVDI

**HOSPITAL NAME**

Animal Health  
Partners

**REFERRING VET**

Dr. Debbie Reynolds

**INVOICE**

53454

**DATE**

8-13-22