



PATIENT PRESENTING CLINICAL SIGNS

Scotty Chavez
 Owner noticed that the patient's mouth hasn't been able to shut since 8/12/22 - gurgling/bleeding ever starting to sneeze - has been wanting to set up a dental.

SPECIES COMPUTED TOMOGRAPHY OF THE SKULL

Canine
 A high resolution pre- and post-contrast CT study of the skull is provided for review.

COMPUTED TOMOGRAPHIC FINDINGS

BREED
 Terrier X
SEX
 MN
 The tooth elements 101-107, 109, 110, 201, 202, 205-207, 209, 210, 301-303, 306, 311, 402, 403, 406, 410 and 411 are absent. All remaining teeth present with a marked amount of mineral attenuating material attached to the crowns and a marked widening of the periodontal space & horizontal bone loss of the alveolar bone. Triadan 208 presents advanced resorption of the roots and is displaced, coming in contact with triadan 309. The root of triadan 204 is perforating the left nasal cavity and at the same level moderate soft tissue swelling is seen in the left nasal cavity. Focal destruction of the conchal structures in the rostral aspect of the left nasal cavity is appreciated.

The nasal cavity presents the expected aerated spaces between thin & even conchae and turbinates with smooth mucosal lining.

AGE
 16 Years
 Both temporomandibular joints present congruent joint spaces with even subchondral bone surfaces and are considered within normal limits.

INTERPRETED BY
 Sebastian Schaub, DVM
 Dr. med. vet. DipECVDI
 Both tympanic bullae are aerated, the mucosal lining is not seen, the bony wall is smooth and thin. The external ear canals are within normal limits.

The submandibular and medial retropharyngeal lymph nodes are prominent and elongated with a normal short-to-long-axis-ratio is < 0.5, the attenuation pattern is uniform.

The vertebral endplates C4/C5 present moderate spondylosis formation.

HOSPITAL NAME COMPUTED TOMOGRAPHIC DIAGNOSIS

- Scottsdale Veterinary Clinic
- Generalized advanced periodontal disease of all remaining teeth with oronasal fistula formation 204
 - Secondary left sided odontogenic destructive rhinitis
 - Marked generalized dental tartar
 - Lymphadenopathy tributary lymph nodes of the skull

REFERRING VET
 Dr. Samantha Gans

INTERPRETATION OF THE FINDINGS & FURTHER RECOMMENDATIONS

INVOICE
 53455
 The findings are consistent with advanced dental disease with displacement of triadan 208 - potentially explaining the presenting clinical signs of not being able to shut the mouth. The sneezing can be explained by the oronasal fistula originating from triadan 208. A complete dental workup with extraction of all teeth ± triadan 304 is considered as the therapy of choice.

DATE
 8-13-22
 Secondary reactive hyperplasia of the tributary lymph nodes.



PATIENT

Scotty Chavez

SPECIES

Canine

BREED

Terrier X

SEX

MN

AGE

16 Years

INTERPRETED BY

Sebastian Schaub, DVM
Dr. med. vet. DipECVDI

HOSPITAL NAME

Scottsdale Veterinary
Clinic

REFERRING VET

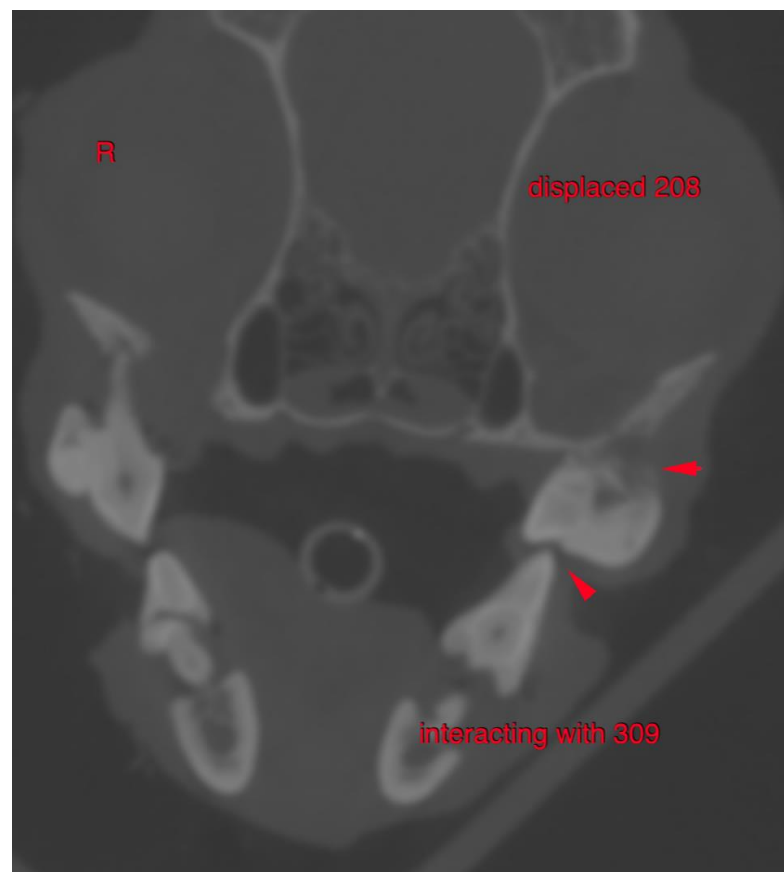
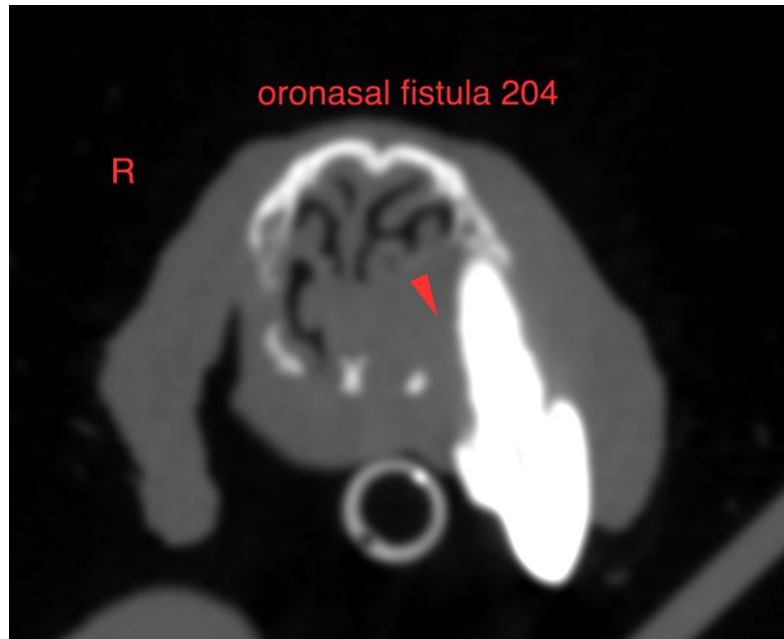
Dr. Samantha Gans

INVOICE

53455

DATE

8-13-22





PATIENT

Scotty Chavez

SPECIES

Canine

BREED

Terrier X

SEX

MN

AGE

16 Years

INTERPRETED BY

Sebastian Schaub, DVM
Dr. med. vet. DipECVDI

HOSPITAL NAME

Scottsdale Veterinary
Clinic

REFERRING VET

Dr. Samantha Gans

INVOICE

53455

DATE

8-13-22

The information and recommendations provided are based on the images presented by the referring veterinarian/sonographer. No evaluation can be communicated regarding pathology that was not visible in the image/video clips provided.

Thank you for this referral. If the clinical or image interpretation does not parallel your findings or if I can be of any further assistance please contact me.

Sebastian Schaub, Sebastian Schaub, DVM, Dr. med. vet. DipECVDI
sebast.schaub@gmail.com