



PATIENT PRESENTING CLINICAL SIGNS

Rex Navarro History: Unilateral epistaxis for about 2 weeks, more common when the patient gets excited. Abnormal PE/Chem/CBC/UA Results: no epistaxis noted during CT, no abnormalities of the oral cavity noted either.

SPECIES COMPUTED TOMOGRAPHIC STUDY OF THE SKULL

Canine A high resolution pre- and post-contrast CT study of the skull is provided for review.

BREED COMPUTED TOMOGRAPHIC FINDINGS

Doberman The pictured parts of the dentition are complete and unremarkable in all jaw quadrants.

SEX The nasal cavity presents the expected aerated spaces between thin and even conchae and turbinates with smooth mucosal lining.

Neutered Male Both temporomandibular joints present congruent joint spaces with even subchondral bone surfaces and are considered within normal limits.

AGE Both tympanic bullae are aerated, the mucosal lining is not seen, the bony wall is smooth and thin. The external ear canals are within normal limits.

7 Years

INTERPRETED BY The brain presents no deviation from normal anatomy and symmetry. The brain parenchyma is homogeneous and within normal limits for attenuation and distribution of contrast enhancement. The ventricular system is non-dilated and symmetric.

Sebastian Schaub, DVM Dr. med. vet. DipECVDI The submandibular and medial retropharyngeal lymph nodes are small and elongated with a normal short-to-long-axis-ratio is < 0.5, the attenuation and contrast enhancement pattern is uniform.

HOSPITAL NAME COMPUTED TOMOGRAPHIC DIAGNOSIS

Mobile Pet Imaging • Normal skull

INTERPRETATION OF THE FINDINGS & FURTHER RECOMMENDATIONS

REFERRING VET There is no evidence for neoplastic disease of the nasal cavity or foreign body related rhinitis. Potentials for epistaxis include immune mediated disease, non-specific rhinitis (e.g. lymphocytic plasmocytic), hyperviscosity syndrome (e.g. Leishmaniosis), other causes for coagulopathy or systemic hypertension.

Meaux

INVOICE

12528

DATE

8/13/21



PATIENT

Rex Navarro

SPECIES

Canine

BREED

Doberman

SEX

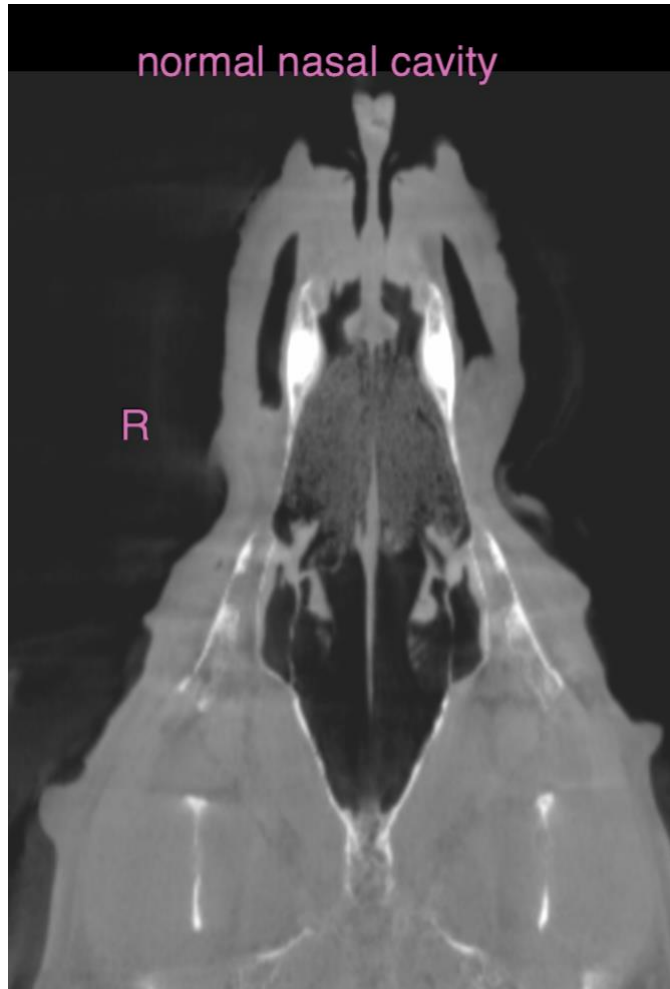
Neutered Male

AGE

7 Years

INTERPRETED BY

Sebastian Schaub,
DVM Dr. med. vet.
DipECVDI



HOSPITAL NAME

Mobile Pet Imaging

The information and recommendations provided are based on the images presented by the referring veterinarian. No evaluation can be communicated regarding pathology that was not visible in the image/video clips provided.

REFERRING VET

Meaux

Thank you for this referral. If the clinical or image interpretation does not parallel your findings or if I can be of any further assistance please contact me.

Sebastian Schaub, Sebastian Schaub, DVM, Dr. med. vet. DipECVDI
sebast.schaub@gmail.com

INVOICE

12528

DATE

8/13/21



PATIENT

Rex Navarro

SPECIES

Canine

BREED

Doberman

SEX

Neutered Male

AGE

7 Years

INTERPRETED BY

Sebastian Schaub,
DVM Dr. med. vet.
DipECVDI

HOSPITAL NAME

Mobile Pet Imaging

REFERRING VET

Meaux

INVOICE

12528

DATE

8/13/21