



PATIENT PRESENTING CLINICAL SIGNS

Misek Vukovic History: Start this morning, heavy breathing and doing a snoring sound, prior to that he was health with no concerns.

SPECIES Abnormal PE/Chem/CBC/UA Results: severe upper respiratory noise and heavy abdominal breathing. No heart murmur, no crackles or wheezes. Blood work and UA: N/A

Canine

RADIOGRAPHIC STUDY OF THE THORAX

BREED A complete set of radiographs of the thorax is provided for review.

Yorkshire Terrier

RADIOGRAPHIC FINDINGS

SEX

Male

The surrounding bony structures are within normal limits.

The extrathoracic soft tissues present homogeneous without abnormalities.

The heart is of normal size and shape, there is no evidence of cardiac chamber or vascular enlargement. The pulmonary vasculature is within normal limits.

AGE

7 Years

The cranial mediastinum presents the expected soft tissue opacity. The mediastinal width is less than twice the width of the vertebral column at the same level.

INTERPRETED BY

Sebastian Schaub,
DVM Dr. med. vet.
DipECVDI

Significant flattening of the cervical segment of the trachea is noted.

The bronchial tree presents with thin walls and tapers uniformly towards the periphery as expected. The lung parenchyma presents the expected architecture and opacity; the intrapulmonary vascular branching is seen up to the third order lung vessels.

HOSPITAL NAME

Truscott AH

The diaphragm is well delineated with even surface and the expected mild cranial bulging of the diaphragmatic cupola.

RADIOGRAPHIC DIAGNOSIS

REFERRING VET

Dr. Erini Abraham

- Tracheal collapse
- Mild obesity

INTERPRETATION OF THE FINDINGS & FURTHER RECOMMENDATIONS

INVOICE

12531

The findings are consistent with collapse of the cervical tracheal segment. The finding explains the clinical signs. Endoscopy can be used for further grading of the tracheal collapse and check if accompanying bronchial collapse is present. Depending on the development of clinical signs, tracheal stenting might be an option. Weight management should be considered as well.

DATE

8/13/21



PATIENT

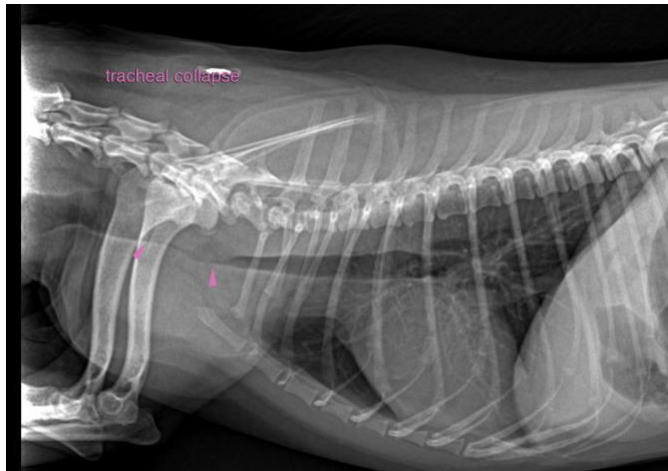
Misek Vukovic

SPECIES

Canine

BREED

Yorkshire Terrier



SEX

Male

The information and recommendations provided are based on the images presented by the referring veterinarian. No evaluation can be communicated regarding pathology that was not visible in the image/video clips provided.

AGE

7 Years

Thank you for this referral. If the clinical or image interpretation does not parallel your findings or if I can be of any further assistance please contact me.

Sebastian Schaub, Sebastian Schaub, DVM, Dr. med. vet. DipECVDI
sebast.schaub@gmail.com

INTERPRETED BY

Sebastian Schaub,
DVM Dr. med. vet.
DipECVDI

HOSPITAL NAME

Truscott AH

REFERRING VET

Dr. Erini Abraham

INVOICE

12531

DATE

8/13/21