



PATIENT PRESENTING CLINICAL SIGNS

Maggie Weaver History: Acute pain in L/S spine.
Abnormal PE/Chem/CBC/UA Results:

SPECIES COMPUTED TOMOGRAPHIC STUDY OF THE LUMBAR SPINE

Canine A high resolution plain and myelographic CT study of the lumbar spine is provided for review.

COMPUTED TOMOGRAPHIC FINDINGS

BREED
Anatolian The vertebral endplates T13/L1, L2/L3 and L7/S1 present moderate spondylosis formation. All facet joints of the lumbar spine show mild to moderate spondylosis formation.

SEX
The intervertebral disc T13/L1 is mildly protruding into the vertebral canal.

Spayed Female The lumbosacral intervertebral disc is mildly protruding into the vertebral canal. The vertebral endplates L7/S1 present a mild rough surface of the subchondral bone.

AGE
The spinous process of S1 & S2 are not fused.

9 Years 10 Months Both iliosacral joints show moderate degenerative changes with evidence of ankylosis of the right iliosacral joint.

INTERPRETED BY
Both coxofemoral joints present mild to moderate osteophyte new bone formation.

Sebastian Schaub,
DVM Dr. med. vet.
DipECVDI

COMPUTED TOMOGRAPHIC DIAGNOSIS

- Mild intervertebral disc protrusion T13/L1 and L7/S1 without compressive myelopathy
- Mild chronic remodeling vertebral endplates lumbosacral junction
- Serial spondylarthrosis
- Degenerative osteoarthritis both coxofemoral joints
- Lumbosacral transitional vertebra – Type I
- Spondylosis deformans

HOSPITAL NAME

Southern Oregon VSC

REFERRING VET INTERPRETATION OF THE FINDINGS & FURTHER RECOMMENDATIONS

Dr. Fugazzi The current CT study presents with multiple chronic degenerative changes of the lumbar spine, lumbosacral junction and pelvis but no macromorphological abnormality explaining the acute onset of pain. An acute on chronic insult can be a potential here. Consider rest and pain management and reevaluation of the patient in 4-6 weeks, early if clinical signs deteriorate.

INVOICE

12520

DATE

8/13/21



PATIENT

Maggie Weaver

SPECIES

Canine

BREED

Anatolian

SEX

Spayed Female

AGE

9 Years 10 Months

INTERPRETED BY

Sebastian Schaub,
DVM Dr. med. vet.
DipECVDI

HOSPITAL NAME

Southern Oregon VSC

REFERRING VET

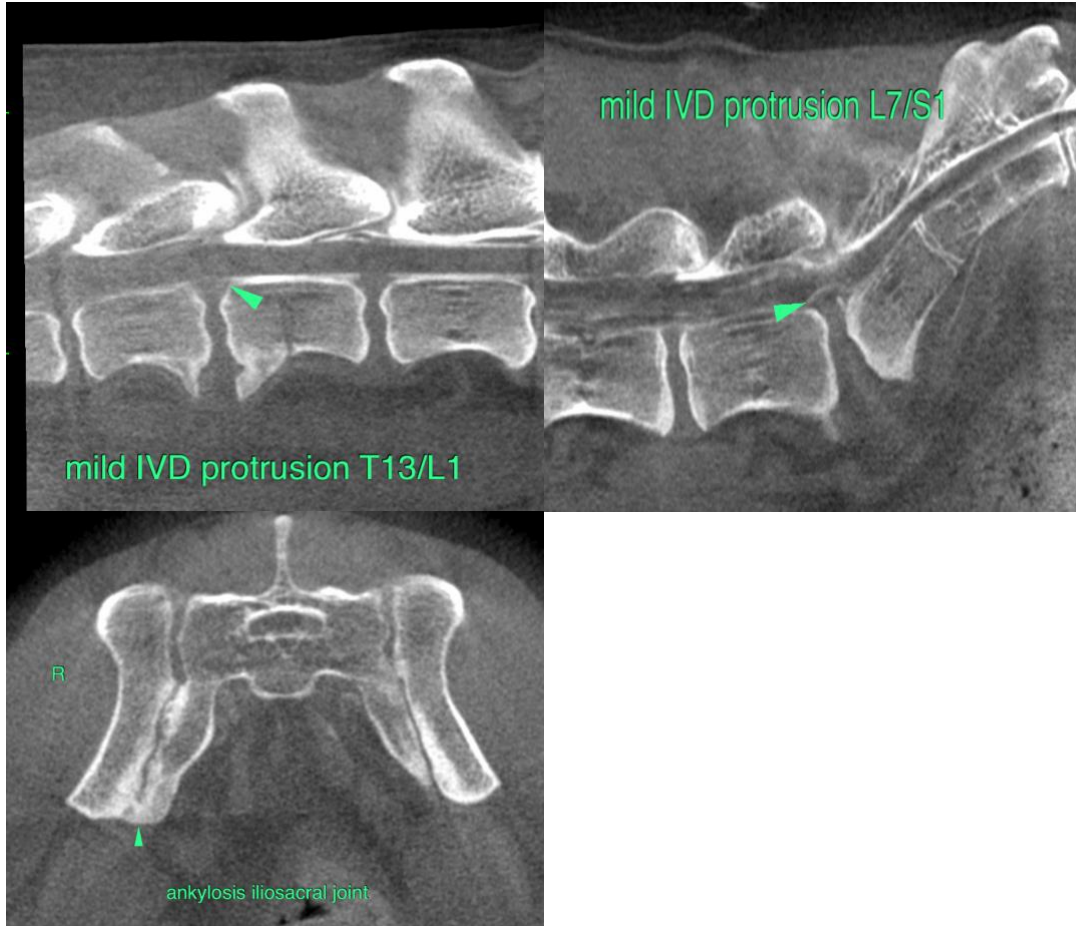
Dr. Fugazzi

INVOICE

12520

DATE

8/13/21



The information and recommendations provided are based on the images presented by the referring veterinarian. No evaluation can be communicated regarding pathology that was not visible in the image/video clips provided.

Thank you for this referral. If the clinical or image interpretation does not parallel your findings or if I can be of any further assistance please contact me.

Sebastian Schaub, Sebastian Schaub, DVM, Dr. med. vet. DipECVDI
sebast.schaub@gmail.com



PATIENT

Maggie Weaver

SPECIES

Canine

BREED

Anatolian

SEX

Spayed Female

AGE

9 Years 10 Months

INTERPRETED BY

Sebastian Schaub,
DVM Dr. med. vet.
DipECVDI

HOSPITAL NAME

Southern Oregon VSC

REFERRING VET

Dr. Fugazzi

INVOICE

12520

DATE

8/13/21