



**PATIENT PRESENTING CLINICAL SIGNS**

**Lily Ranson** History: History of hip dysplasia surgery of the left hip and Left limb amputation after an injury in the same limb, both surgeries done at the previous vet. Started crying intermittently, unable to ambulate on her RHL, and falling over. This happened 3 times. Started on Metacam PO q24.

**SPECIES**

Abnormal PE/Chem/CBC/UA Results: Pain around the hip area. Blood work is unremarkable.  
Canine

**RADIOGRAPHIC STUDY OF THE LUMBAR SPINE & PELVIS**

**BREED**

Radiographs of the lumbar spine and pelvis in two orthogonal imaging planes are provided for review.

Spitz Mix

**RADIOGRAPHIC FINDINGS**

**SEX**

The osseous and surrounding soft tissue structures of the lumbar spine are within normal limits.

Spayed Female

The right coxofemoral joint presents with advanced osteophyte new bone formation, the right femoral head is misshapen and the joint space of the right coxofemoral joint is incongruent. The right acetabular groove is shallow and the centered of the right femoral head is lateral to the dorsal acetabular rim. The patella of the right stifle joint is superimposed on the medial femoral condyle.

**AGE**

7 Years

The left femoral head is note appreciated, the left acetabular groove is filled with osseous material. The left hind limb is amputated in the mid diaphysis of the femur and moderate atrophy of the proximal segment of the left femur is present.

**INTERPRETED BY**

Sebastian Schaub,  
DVM Dr. med. vet.  
DipECVDI

**RADIOGRAPHIC DIAGNOSIS**

- History of hip dysplasia with advanced degenerative osteoarthritis right coxofemoral joint
- Right sided medial patellar luxation
- History of left sided femoral head osteotomy and amputation of the left hind limb
- Normal lumbar spine

**HOSPITAL NAME**

Truscott AH

**INTERPRETATION OF THE FINDINGS & FURTHER RECOMMENDATIONS**

The radiographic study presents no specific abnormality, explaining the described acute clinical signs. Due to the age of the patient and no history of preceding gait anomalies of the right hind limb, the clinical relevance of the medial patellar luxation is unclear.

**REFERRING VET**

Dr. Erini Abraham

**INVOICE**

16861

**DATE**

8/12/22



**PATIENT**

Lily Ranson

**SPECIES**

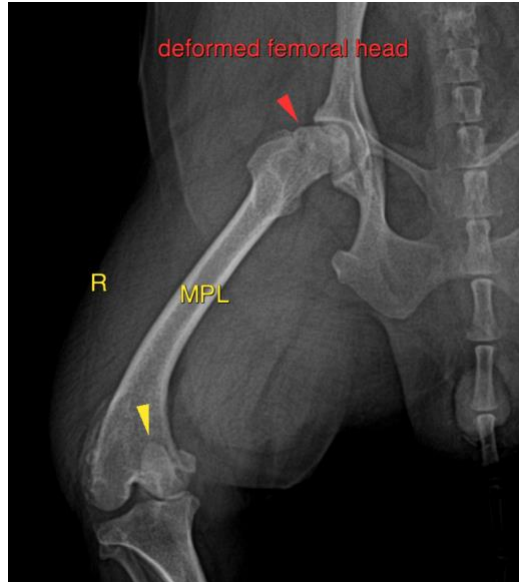
Canine

**BREED**

Spitz Mix

**SEX**

Spayed Female



**AGE**

7 Years

**The information and recommendations provided are based on the images presented by the referring veterinarian/sonographer. No evaluation can be communicated regarding pathology that was not visible in the image/video clips provided.**

Thank you for this referral. If the clinical or image interpretation does not parallel your findings or if I can be of any further assistance please contact me.

**INTERPRETED BY**

Sebastian Schaub,  
DVM Dr. med. vet.  
DipECVDI

**Sebastian Schaub**, Sebastian Schaub, DVM, Dr. med. vet. DipECVDI  
sebast.schaub@gmail.com

**HOSPITAL NAME**

Truscott AH

**REFERRING VET**

Dr. Erini Abraham

**INVOICE**

16861

**DATE**

8/12/22