



PATIENT PRESENTING CLINICAL SIGNS

Bella Adams History: sudden onset of sever vomiting
Abnormal PE/Chem/CBC/UA Results: cPLI is elevated

SPECIES RADIOGRAPHIC STUDY OF THE ABDOMEN

Canine A complete set of radiographs of the abdomen is provided for review.

BREED RADIOGRAPHIC FINDINGS

Labrador Retriever

The surrounding bony structures are within normal limits.

No abnormalities of the extraabdominal soft tissues are noted. The abdominal wall is smooth and thin.

SEX The serosal detail is maintained throughout the peritoneal and retroperitoneal space.

Spayed Female The liver is appropriate in position, size and presents uniform opacity.

AGE The splenic head is in the anticipated position and within normal limits for size and opacity. The splenic body and tail are considered normal for position, size, shape and opacity.

8 Years Both kidneys are seen and present with normal size, shape, delineation and opacity. The urinary bladder is in its anticipated position. No radiopaque calculi are noted throughout the upper and lower urinary tract.

INTERPRETED BY

Sebastian Schaub,
DVM Dr. med. vet.
DipECVDI

The stomach is in its anticipated position and contains a mild amount of gas.

The small intestinal loops are of even diameter and non-dilated, a small amount of gas is seen within the small intestinal loops and considered within normal limits.

HOSPITAL NAME

St. Catharine's AH

The colon is seen in the expected position and presents with appropriate content.

RADIOGRAPHIC DIAGNOSIS

REFERRING VET • Structural normal abdomen with mild gas distended stomach

Dr. Boctor

INTERPRETATION OF THE FINDINGS & FURTHER RECOMMENDATIONS

INVOICE The radiographic study of the abdomen presents without abnormalities. There is no evidence of radiopaque foreign material or signs for gastrointestinal mechanical obstruction. The mild gas distension of the stomach can be due to the vomiting ± stress. Recommend empirical management. If clinical signs of potential gastritis are refractory to therapy, consider follow up radiographs or a complete abdominal ultrasound examination.

12517

DATE

8/12/21



PATIENT

Bella Adams

SPECIES

Canine

BREED

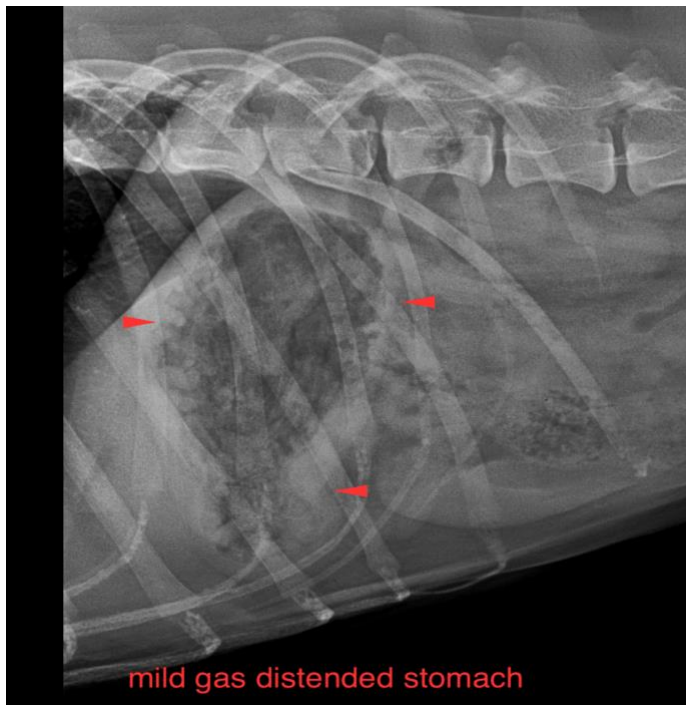
Labrador Retriever

SEX

Spayed Female

AGE

8 Years



The information and recommendations provided are based on the images presented by the referring veterinarian. No evaluation can be communicated regarding pathology that was not visible in the image/video clips provided.

INTERPRETED BY

Sebastian Schaub,
DVM Dr. med. vet.
DipECVDI

Thank you for this referral. If the clinical or image interpretation does not parallel your findings or if I can be of any further assistance please contact me.

HOSPITAL NAME

St. Catharine's AH

Sebastian Schaub, Sebastian Schaub, DVM, Dr. med. vet. DipECVDI
sebast.schaub@gmail.com

REFERRING VET

Dr. Boctor

INVOICE

12517

DATE

8/12/21