



PATIENT PRESENTING CLINICAL SIGNS

EMMY SEKULA History: Emmy is a 2 years old, female, not spayed Yorkie, presented with lethargy, shaking and not eating today. Family cannot rule out any access to FB or dietary indiscretion.

SPECIES Abnormal PE/Chem/CBC/UA Results: Arched back and tense abdomen on palpation. 4% dehydration. Blood work show leukocytosis, monocytosis, neutrophilia. Chemistry WNL. UA: N/A

Canine

RADIOGRAPHIC STUDY OF THE ABDOMEN

BREED Radiographs of the abdomen in three imaging planes are provided for review.

Yorkshire Terrier

RADIOGRAPHIC FINDINGS

SEX

The surrounding bony structures are within normal limits.

Female

No abnormalities of the extraabdominal soft tissues are noted. The abdominal wall is smooth and thin.

The serosal detail is maintained throughout the peritoneal and retroperitoneal space.

AGE

The liver is appropriate in position, size and presents uniform opacity.

2 Years

The splenic head is in the anticipated position and within normal limits for size and opacity. The splenic body and tail are considered normal for position, size, shape and opacity.

INTERPRETED BY

Sebastian Schaub,
DVM Dr. med. vet.
DipECVDI

Both kidneys are seen and present with normal size, shape, delineation and opacity. The urinary bladder is in its anticipated position. No radiopaque calculi are noted throughout the upper and lower urinary tract.

HOSPITAL NAME

The stomach is in its anticipated position and contains a mild to moderate amount of fluid and soft tissue material.

Medhat Meawad

The small intestinal loops are of even diameter and non-dilated, the small intestinal loops contain multiple gas bubbles and fluid.

REFERRING VET

The colon is seen in the expected position and presents with appropriate content.

Dr. Erini Abraham

RADIOGRAPHIC DIAGNOSIS

INVOICE

- Mild fluid filled stomach
- Foamy and fluidity content in intestinal tract

12507

INTERPRETATION OF THE FINDINGS & FURTHER RECOMMENDATIONS

DATE

The pattern of the gastrointestinal tract is suggestive for gastritis/gastroenteritis with possible secondary functional gastric emptying disorder. There is no evidence of radiopaque foreign material

8/11/21



PATIENT

Emmy Sekula

or signs for gastrointestinal mechanical obstruction. If clinical signs are refractory to empirical therapy, follow up radiographs of the abdomen or a complete abdominal ultrasound examination are recommended. If not done so yet, consider complementing blood work by cpl to screen for pancreatitis.

SPECIES

Canine

BREED

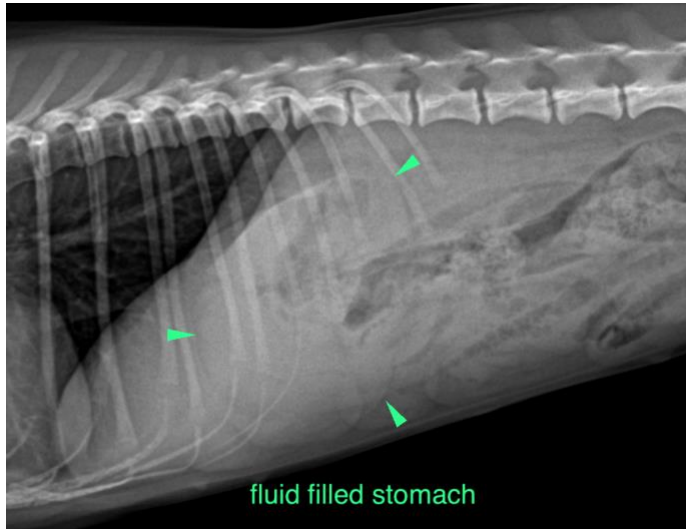
Yorkshire Terrier

SEX

Female

AGE

2 Years



The information and recommendations provided are based on the images presented by the referring veterinarian. No evaluation can be communicated regarding pathology that was not visible in the image/video clips provided.

INTERPRETED BY

Sebastian Schaub,
DVM Dr. med. vet.
DipECVDI

Thank you for this referral. If the clinical or image interpretation does not parallel your findings or if I can be of any further assistance please contact me.

HOSPITAL NAME

Medhat Meawad

Sebastian Schaub, Sebastian Schaub, DVM, Dr. med. vet. DipECVDI
sebast.schaub@gmail.com

REFERRING VET

Dr. Erini Abraham

INVOICE

12507

DATE

8/11/21