


PATIENT PRESENTING CLINICAL SIGNS

Turk Tesla Pt started with diarrhea yesterday and is now liquid and frequent. Pt hasn't had an appetite for about 2 days now. No change in food, new treat. Pt might have gotten into something outside, but o unsure. Vomited bile once yesterday. NSF on PE, bw w/ cpl pending

SPECIES RADIOGRAPHIC STUDY OF THE ABDOMEN

Canine Radiographs of the abdomen in three imaging planes are provided for review.

BREED RADIOGRAPHIC FINDINGS

Boston Terrier The surrounding bony structures are within normal limits.
 No abnormalities of the extraabdominal soft tissues are noted. The abdominal wall is smooth and thin.

SEX The serosal detail is maintained throughout the peritoneal and retroperitoneal space.

Neutered Male The liver is appropriate in position, size and presents uniform opacity.

AGE The splenic head is in the anticipated position and within normal limits for size and opacity. The splenic body and tail are considered normal for position, size, shape and opacity.

9 Years Both kidneys are seen and present with normal size, shape, delineation and opacity. The urinary bladder is in its anticipated position. No radiopaque calculi are noted throughout the upper and lower urinary tract.

INTERPRETED BY

Sebastian Schaub,
 DVM Dr. med. vet.
 DipECVDI

The stomach is in its anticipated position and contains a small volume of foamy soft tissue material. The small intestinal loops are of even diameter and non-dilated, a small amount of gas is seen within the small intestinal loops and considered within normal limits.

HOSPITAL NAME

The Pet Hospital of
 Stratford

The colon is seen in the expected position, is mildly distended by gas ± small volume of fluid and appears tubular hypomotile.

RADIOGRAPHIC DIAGNOSIS

- Hypomotile appearing colon with mild gas filling

REFERRING VET

Dr. Robert Bashkin

INTERPRETATION OF THE FINDINGS & FURTHER RECOMMENDATIONS

The appreciated pattern of the gastrointestinal tract is highly suggestive for gastroenteritis – e.g. dietary indiscretion, parasitic infection, dysbacteriosis, pancreatitis. There is no evidence of radiopaque foreign material, abnormal gas pattern or signs for gastrointestinal mechanical obstruction.

INVOICE

44621

DATE

8/10/23



PATIENT

Turk Tesla

SPECIES

Canine

BREED

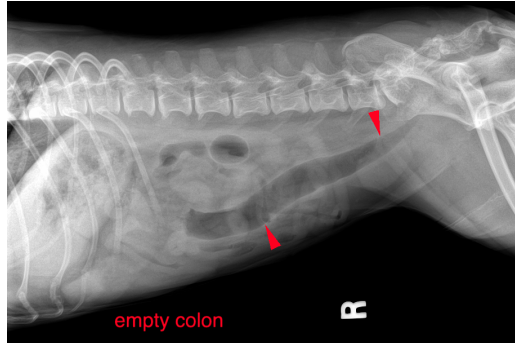
Boston Terrier

SEX

Neutered Male

AGE

9 Years



The information and recommendations provided are based on the images presented by the referring veterinarian. No evaluation can be communicated regarding pathology that was not visible in the image/video clips provided.

Thank you for this referral. If the clinical or image interpretation does not parallel your findings or if I can be of any further assistance please contact me.

Sebastian Schaub, Sebastian Schaub, DVM, Dr. med. vet. DipECVDI
sebast.schaub@gmail.com

INTERPRETED BY

Sebastian Schaub,
DVM Dr. med. vet.
DipECVDI

HOSPITAL NAME

The Pet Hospital of
Stratford

REFERRING VET

Dr. Robert Bashkin

INVOICE

44621

DATE

8/10/23