


PATIENT PRESENTING CLINICAL SIGNS

PATIENT Poe (Potatoe) Sheehy **PRESENTING CLINICAL SIGNS** Owner notes that he is anxious and is working with a trainer. Wonders if part of his trying to bite other dogs is due to back pain.

SPECIES Abnormal PE/Chem/CBC/UA Results: Exam: upper resp stridor, kyphosis no neuro deficits , mild discomfort over t-l pending cbc chem

Canine

RADIOGRAPHIC STUDY OF THE THORACIC & LUMBAR SPINE AND PELVIS

BREED Radiographs of the thoracic and lumbar spine and the pelvis in two orthogonal imaging planes are provided for review.

French Bulldog

RADIOGRAPHIC FINDINGS

SEX

Neutered Male

T3, T4, T6 to T12 and L3-L6 present as hemivertebra. Segmental kyphosis and scoliosis of the lumbar spine level L3 to L6 is appreciated. Due to the hemivertebra, the respective intervertebral disc spaces are distorted or collapsed. Multifocal spondylosis formation is seen along the thoracic and lumbar spine.

AGE

3 Years

The osseous and surrounding soft tissue structures of the pelvis are within normal limits. Both coxofemoral joints present smooth osseous margins, the joint spaces are mildly widened and diverging.

RADIOGRAPHIC DIAGNOSIS

INTERPRETED BY

Sebastian Schaub,
 DVM Dr. med. vet.
 DipECVDI

- Multiple hemivertebra along the thoracic and lumbar spine
- Secondary kyphosis and scoliosis mid segment of lumbar spine
- Mild hip dysplasia – likely clinically not relevant
- Spondylosis deformans

INTERPRETATION OF THE FINDINGS & FURTHER RECOMMENDATIONS

HOSPITAL NAME

Northshore VH

The appreciated congenital changes along the thoracic and lumbar spine might predispose for discopathy due to altered biomechanics. An underlying cause for possible back pain cannot be specified in the radiographic study. If neurological deficits develop, recommend complementing workup by cross-sectional imaging of the spine.

REFERRING VET

Dr. Brita Kiffney

INVOICE

44570

DATE

8/10/23



PATIENT

Poe (Potatoe) Sheehy

SPECIES

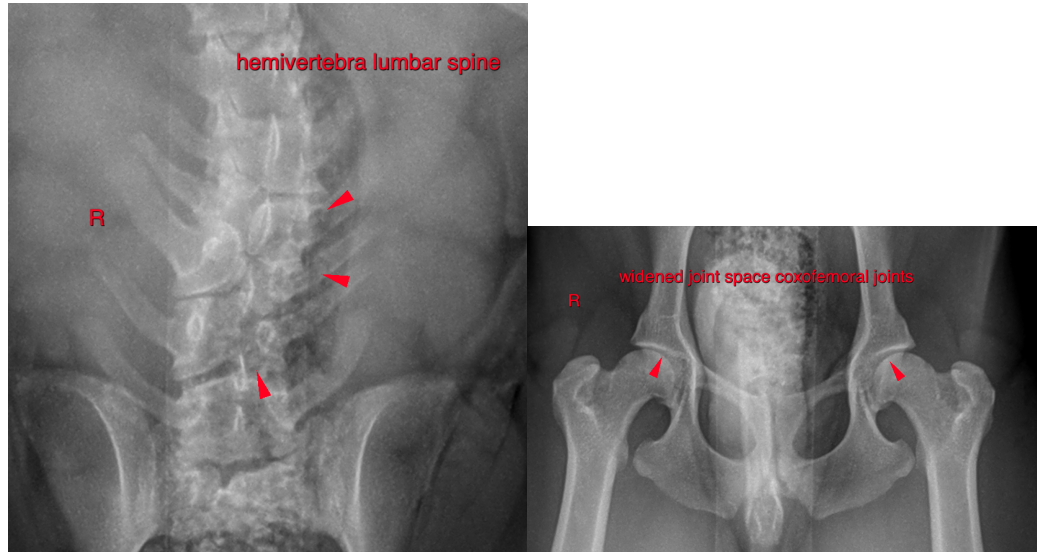
Canine

BREED

French Bulldog

SEX

Neutered Male



AGE

3 Years

The information and recommendations provided are based on the images presented by the referring veterinarian. No evaluation can be communicated regarding pathology that was not visible in the image/video clips provided.

Thank you for this referral. If the clinical or image interpretation does not parallel your findings or if I can be of any further assistance please contact me.

INTERPRETED BY

Sebastian Schaub,
DVM Dr. med. vet.
DipECVDI

Sebastian Schaub, Sebastian Schaub, DVM, Dr. med. vet. DipECVDI
sebast.schaub@gmail.com

HOSPITAL NAME

Northshore VH

REFERRING VET

Dr. Brita Kiffney

INVOICE

44570

DATE

8/10/23