


PATIENT PRESENTING CLINICAL SIGNS

Gunner Gordon P present to AEHV for swelling on R side of head, drooling and difficulty opening mouth for 7-10 days. O has been giving meloxicam and gabapentin. P has not been eating, still drinking water. P has had diarrhea and has been trying to vomit. P had mass removal last week.

SPECIES

Canine

Abnormal PE/Chem/CBC/UA Results: Elevated WBC (34)

COMPUTED TOMOGRAPHIC STUDY OF THE SKULL
BREED

Labrador

A high resolution pre- and post-contrast CT study of the skull is provided for review.

COMPUTED TOMOGRAPHIC FINDINGS
SEX

Male

Parts of the crown of triadan 104 are absent and the pulp cavity is exposed to the dental surface; the periapical periodontal space is mildly widened. Triadan 105, 106 and 205 present a widened periodontal space. The tooth element 207 is absent.

The temporal muscles are subjectively swollen and present a heterogeneous contrast uptake in the caudal aspect.

AGE

10 Years

In the subcutaneous tissue lateral to the right masseter muscle, an ill-defined, homogeneous soft tissue swelling is appreciated. Post contrast administration the soft tissue swelling has a multiloculated appearance with multiple septa and fluid attenuating pockets. Extending from the soft tissue swelling caudally and mildly medially, a peripheral contrast enhancing and central fluid attenuating extension is seen, that can be followed up to the rostradorsal aspect of the right medial retropharyngeal lymph nodes - crossing the horizontal segment of the right external ear canal ventrally.

INTERPRETED BY

Sebastian Schaub,
 DVM Dr. med. vet.
 DipECVDI

The nasal cavity presents the expected aerated spaces between thin & even conchae and turbinates with smooth mucosal lining.

HOSPITAL NAME

Animal Emergency
 Hospital Volusia

Both temporomandibular joints present congruent joint spaces with even subchondral bone surfaces and are considered within normal limits.

The right tympanic bulla is partially filled with gravity dependent, fluid attenuating material; the osseous lining of the right tympanic bulla is thin and smooth. The external ear canals present moderate shell-like mineralization of the wall.

REFERRING VET

Dr. Bogosian

The brain presents no deviation from normal anatomy and symmetry. The brain parenchyma is homogeneous and within normal limits for attenuation and distribution of contrast enhancement. The ventricular system is non-dilated and symmetric.

The medial retropharyngeal lymph nodes bilaterally are prominent.

INVOICE

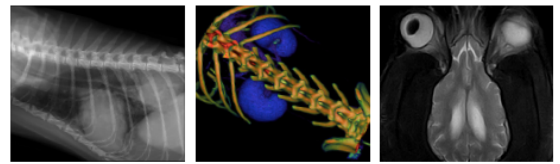
44563

DATE

8/10/23

COMPUTED TOMOGRAPHIC DIAGNOSIS

- Thick walled multiloculated cavitary lesion right buccal region
- Lymphadenopathy medial retropharyngeal lymph nodes bilaterally, R>L
- Equivocal swelling temporal muscle bilaterally
- Right sided otitis media
- Bilateral dystrophic mineralization external ear canals



PATIENT

Gunner Gordon

- Complicated dental fracture 104 with signs of small periapical granuloma formation
- Periodontal disease 105, 106 and 205

INTERPRETATION OF THE FINDINGS & FURTHER RECOMMENDATIONS

SPECIES

Canine

The appreciated subcutaneous swelling is compatible with abscess formation – an underlying cause cannot be specified in the current CT study and preceding perforating trauma or migrating foreign body are potentials. Surgical management is the therapy of choice.

BREED

Labrador

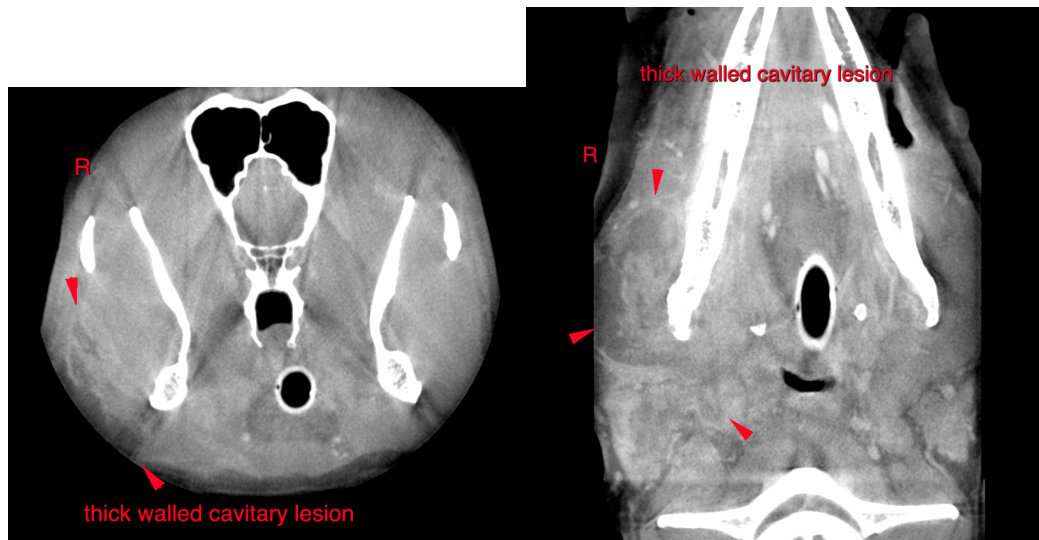
The temporal musculature appears prominent with a heterogeneous contrast enhancement pattern, suspicious for myositis – check clinically for signs of swelling or pain along the temporal muscles.

SEX

Male

AGE

10 Years



INTERPRETED BY

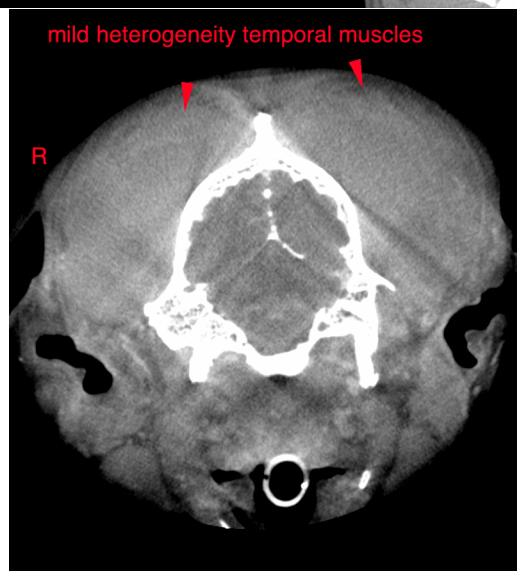
Sebastian Schaub,
DVM Dr. med. vet.
DipECVDI

HOSPITAL NAME

Animal Emergency
Hospital Volusia

REFERRING VET

Dr. Bogosian

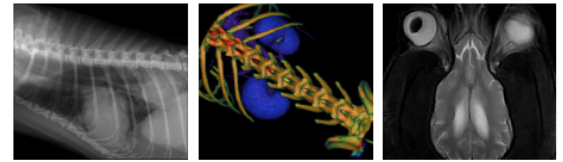


INVOICE

44563

DATE

8/10/23



PATIENT

Gunner Gordon

The information and recommendations provided are based on the images presented by the referring veterinarian. No evaluation can be communicated regarding pathology that was not visible in the image/video clips provided.

SPECIES

Canine

Thank you for this referral. If the clinical or image interpretation does not parallel your findings or if I can be of any further assistance please contact me.

BREED

Labrador

Sebastian Schaub, Sebastian Schaub, DVM, Dr. med. vet. DipECVDI
sebast.schaub@gmail.com

SEX

Male

AGE

10 Years

INTERPRETED BY

Sebastian Schaub,
DVM Dr. med. vet.
DipECVDI

HOSPITAL NAME

Animal Emergency
Hospital Volusia

REFERRING VET

Dr. Bogosian

INVOICE

44563

DATE

8/10/23