



PATIENT PRESENTING CLINICAL SIGNS

Rosalie Vimalarajah Hx last couple months hyporexia, vomiting, losing weight. Now anorexic, left adrenal nodule and heterogenous liver on AUS, pancreatitis

SPECIES COMPUTED TOMOGRAPHY OF THE SKULL, THORAX AND ABDOMEN

Canine A pre- and post-contrast CT study of the skull, thorax and abdomen in a bone, lung and soft tissue reconstruction are provided for review.

BREED COMPUTED TOMOGRAPHIC FINDINGS

Lab X Skull

Triadan 202 is absent. The maxillary and mandibular premolar and molar teeth present ankylosis of the roots and mild resorptive lesions

FS A mild amount of soft tissue attenuating material is seen in the ventral aspect of the nasal cavity bilaterally.

Both temporomandibular joints present congruent joint spaces with even subchondral bone surfaces and are considered within normal limits.

13 Years Both tympanic bullae are aerated, the mucosal lining is not seen, the bony wall is smooth and thin. The external ear canals are within normal limits.

INTERPRETED BY The brain presents no deviation from normal anatomy and symmetry. The brain parenchyma is homogeneous and within normal limits for attenuation and distribution of contrast enhancement. The ventricular system is non-dilated and symmetric.

Sebastian Schaub, DVM
Dr. med. vet. DipECVDI

The submandibular and medial retropharyngeal lymph nodes are small and elongated with a normal short-to-long-axis-ratio is < 0.5, the attenuation and contrast enhancement pattern is uniform.

HOSPITAL NAME Thorax

Animal Health Partners The bony and surrounding soft tissue structures are within normal limits.

The sternal, cranial mediastinal and tracheobronchial lymph nodes are small elongated with a normal short-to-long-axis-ratio is < 0.5, the attenuation and contrast enhancement pattern is uniform and considered within normal limits.

REFERRING VET The cardiovascular structures including the pulmonary vasculature are within normal limits.

Dr. Westgarth The bronchial tree presents with regular branching and tapers uniformly towards the periphery as expected, the bronchial walls are thin and smooth. The bronchus-to-artery ratio is within normal limits.

INVOICE 53393 The lung parenchyma presents the expected architecture and attenuation behavior.

Small incidental gas pockets are seen within the esophageal lumen, there is no evidence of abnormal dilation.

DATE Abdomen

8-10-22 The serosal fat presents normal attenuation behavior. There is no evidence of peritoneal effusion



PATIENT

Rosalie Vimalarajah

or peritonitis.

Both kidneys present within normal limits for size, shape and organ architecture. After contrast administration a bilaterally symmetric and uniform nephro- and pyelogram is noted.

SPECIES

Canine

The cranial pole of the left adrenal gland is mildly enlarged, measuring 8.8 mm in diameter.

The spleen presents with normal shape, even surface, uniformly attenuating parenchyma and homogeneous contrast enhancement, unremarkable.

BREED

Lab X

In the ventral aspect of the left lateral liver lobe, a zone with a scattered fluid attenuation pattern is appreciated and multiple small parenchymal filling defects are seen in the periphery of the heterogeneous attenuating area. At the base of the right division of the liver, a post contrast mild heterogeneous contrast enhancing area is appreciated.

The pancreas is evenly contoured, the pancreatic parenchyma is homogeneous and presents uniform contrast enhancement.

SEX

FS

The position, delineation, wall and content of the gastrointestinal tract are considered within normal limits throughout.

The vertebral endplates L1/L2 and L2/L3 present moderate spondylosis formation.

AGE

13 Years

COMPUTED TOMOGRAPHIC DIAGNOSIS

- Mild nodular enlargement cranial pole left adrenal gland
- Zone with heterogeneous attenuation and contrast enhancement pattern left lateral liver lobe
- Mild non-specific rhinitis
- Generalized periodontal disease with ankylosis and resorptive lesions of the roots
- Spondylosis deformans

INTERPRETED BY

Sebastian Schaub, DVM
Dr. med. vet. DipECVDI

HOSPITAL NAME

Animal Health
Partners

INTERPRETATION OF THE FINDINGS & FURTHER RECOMMENDATIONS

The CT study presents no specific abnormality, explaining the hyporexia. Regarding the ultrasound examination, there is suspicion for pancreatitis, that might be a source for hyporexia.

The heterogeneous zone of the hepatic parenchyma of the left lateral liver lobe is suggestive for zone with multiple small hepatic cyst. Cystadenoma or regeneration nodule might be a potential. The heterogeneous contrast enhancing zone of the base of the right liver lobes is most suggestive for nodular hyperplasia/regeneration nodule. Overall, the odds for malignant hepatic transformation are considered low. Ultrasound guided FNA sampling can be used as advanced minimally invasive diagnostic tool.

REFERRING VET

Dr. Westgarth

INVOICE

53393

The left adrenal nodule is not specific, I consider the odds for incidentaloma/macronodular hyperplasia high. Testing of the pituitary adrenal axis might be beneficial.

DATE

8-10-22



PATIENT

Rosalie Vimalarajah

SPECIES

Canine

BREED

Lab X

SEX

FS

AGE

13 Years

INTERPRETED BY

Sebastian Schaub, DVM
Dr. med. vet. DipECVDI

HOSPITAL NAME

Animal Health
Partners

REFERRING VET

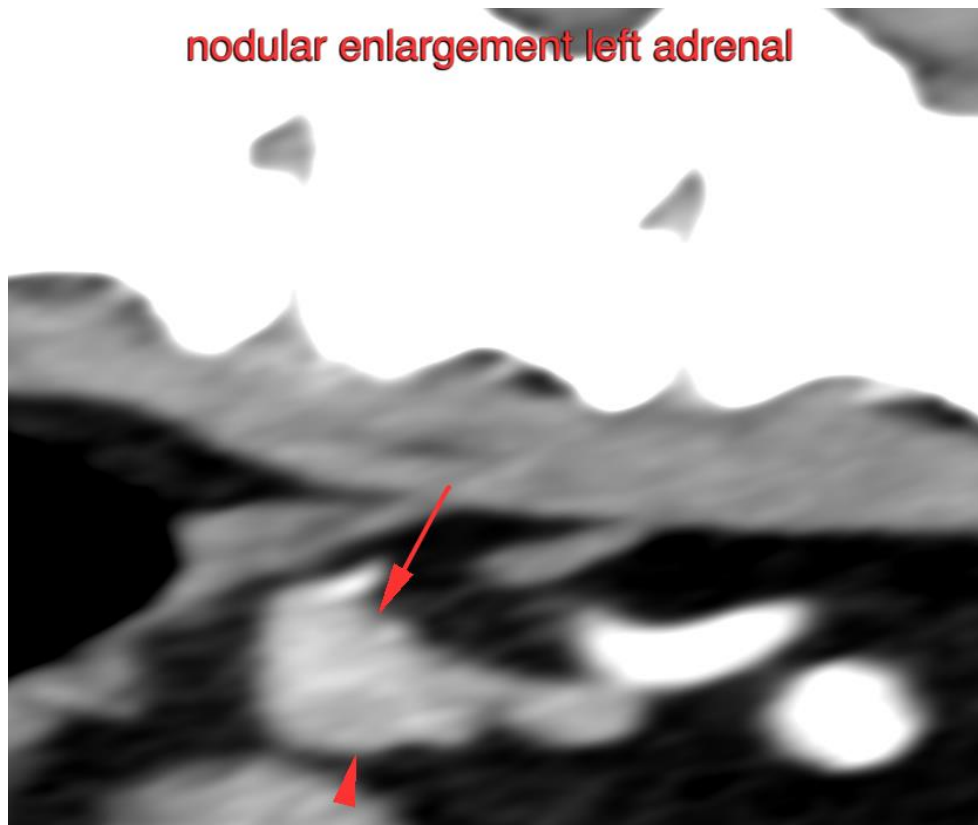
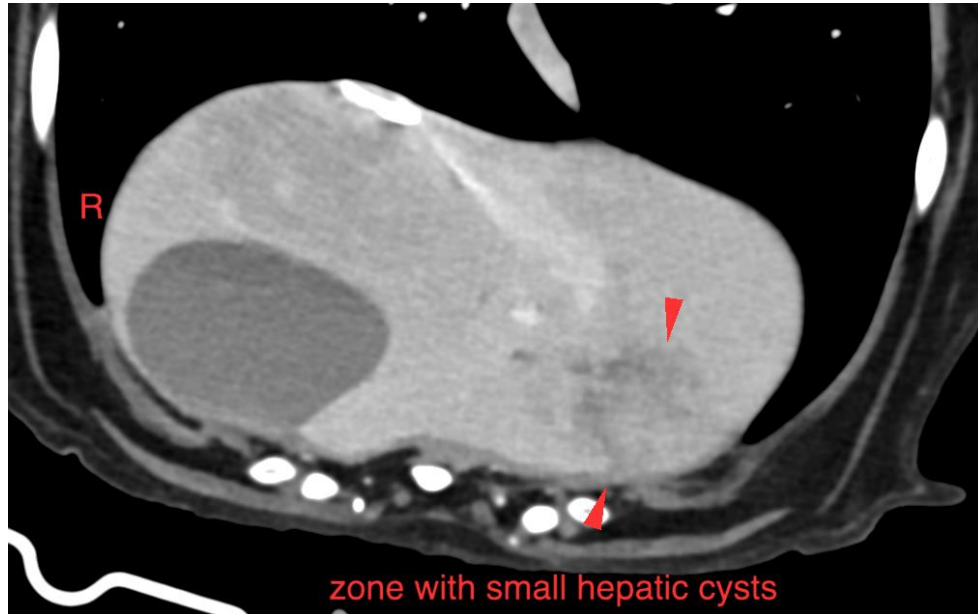
Dr. Westgarth

INVOICE

53393

DATE

8-10-22





PATIENT

Rosalie Vimalarajah

SPECIES

Canine

BREED

Lab X

SEX

FS

AGE

13 Years

INTERPRETED BY

Sebastian Schaub, DVM
Dr. med. vet. DipECVDI

HOSPITAL NAME

Animal Health
Partners

REFERRING VET

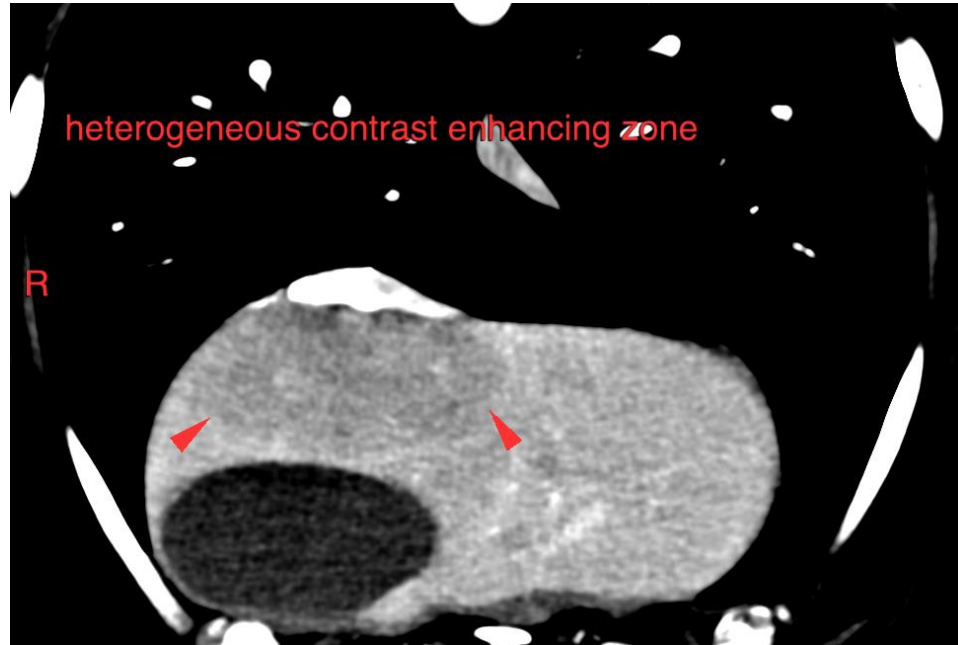
Dr. Westgarth

INVOICE

53393

DATE

8-10-22



The information and recommendations provided are based on the images presented by the referring veterinarian/sonographer. No evaluation can be communicated regarding pathology that was not visible in the image/video clips provided.

Thank you for this referral. If the clinical or image interpretation does not parallel your findings or if I can be of any further assistance please contact me.

Sebastian Schaub, Sebastian Schaub, DVM, Dr. med. vet. DipECVDI
sebast.schaub@gmail.com