



**PATIENT**

Oliver Hutchinson

**PRESENTING CLINICAL SIGNS**

Presented for tachypnea and sneezing/coughing. Has had several bouts of upper respiratory infection treated with doxycycline at previous vet. On exam is tachypneic, pyrexia. Abnormal PE/Chem/CBC/UA Results: FIV/FelV tested at time of neuter as negative. CBC/biochem pending

**SPECIES**

Feline

**RADIOGRAPHIC STUDY OF THE THORAX**

Radiographs of the thorax in three imaging planes are provided for review.

**BREED**

Domestic Shorthair

**RADIOGRAPHIC FINDINGS**

In the pleural cavity, a moderate amount of soft tissue material is appreciated, effacing the cardiovascular structures. The lung lobes are retracted from the thoracic wall and present a decreased volume. Pleural fissure lines are visible.

**SEX**

Male Neutered

The lung parenchyma presents a generalized ground glass opacification.

The surrounding bony structures are within normal limits.

The extrathoracic soft tissues present homogeneous without abnormalities.

**AGE**

10 Months

The trachea is normal in diameter and presents the anticipated course. The luminal outline of the trachea is smooth.

The diaphragm is well delineated with even surface and the expected mild cranial bulging of the diaphragmatic cupola.

**INTERPRETED BY**

Sebastian Schaub, DVM  
Dr. med. vet. DipECVDI

**RADIOGRAPHIC DIAGNOSIS**

- Moderate pleural effusion, R>L

**HOSPITAL NAME**

Mariposa Veterinary Hospital

**INTERPRETATION OF THE FINDINGS & FURTHER RECOMMENDATIONS**

The main finding is the pleural effusion and considerations include transudate or exudate. An underlying cause for the pleural effusion is not appreciated in the radiographic study and further workup warrants tapping the pleural effusion including a complete fluid analysis. Given the young age of the patient pyothorax or underlying cardiac disease are the top differentials. Advanced treatment options depend on the results of the fluid analysis.

**REFERRING VET**

Elyse Hauer

The increase radiopacity of the lung is considered as a sequela to the pleural effusion.

**INVOICE**

53392

**DATE**

8-10-22



**PATIENT**

Oliver Hutchinson

**SPECIES**

Feline

**BREED**

Domestic Shorhair

**SEX**

Male Neutered

**AGE**

10 Months

**INTERPRETED BY**

Sebastian Schaub, DVM  
Dr. med. vet. DipECVDI

**HOSPITAL NAME**

Mariposa Veterinary  
Hospital

**REFERRING VET**

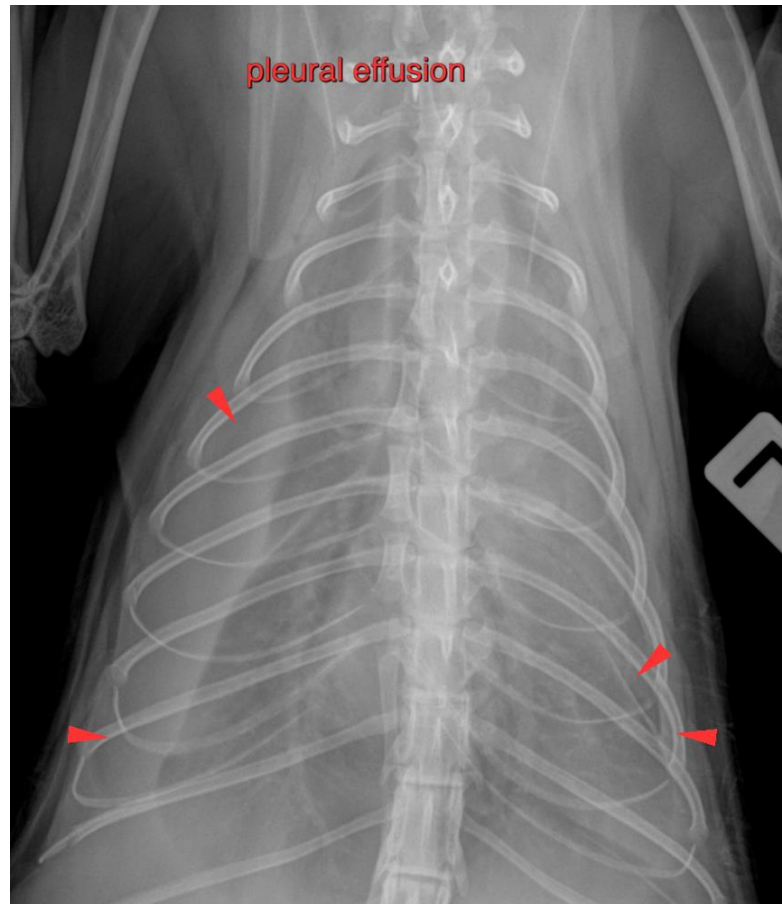
Elyse Hauer

**INVOICE**

53392

**DATE**

8-10-22



The information and recommendations provided are based on the images presented by the referring veterinarian/sonographer. No evaluation can be communicated regarding pathology that was not visible in the image/video clips provided.

Thank you for this referral. If the clinical or image interpretation does not parallel your findings or if I can be of any further assistance please contact me.

**Sebastian Schaub**, Sebastian Schaub, DVM, Dr. med. vet. DipECVDI  
sebast.schaub@gmail.com