



PATIENT

Mason Lewis

SPECIES

Canine

BREED

Havanese Mix

SEX

Male Neutered

AGE

5 Years

INTERPRETED BY

Sebastian Schaub, DVM
Dr. med. vet. DipECVDI

HOSPITAL NAME

The Pet Hospital of
Stratford

REFERRING VET

Dr. Claudia Giuliani

INVOICE

53387

DATE

8-10-22

PRESENTING CLINICAL SIGNS

P presents for limping on LH leg. P initially presented in May for same problem, rec strict cage rest which O was unable to abide by. Was sent home with NSAIDs and Gabapentin - O states responded to these but once medications ran out, P started to limp again. P very active. Possible drawer.

RADIOGRAPHIC STUDY OF THE STIFLE JOINT

Radiographs of both stifle joints in two orthogonal imaging planes are provided for review.

RADIOGRAPHIC FINDINGS

The right stifle joint presents smooth osseous margins and no signs of intracapsular soft tissue swelling.

The periarticular bones of the left stifle joint present moderate osteophyte new bone formation and a moderate intracapsular soft tissue swelling is appreciated.

The volume of the soft tissue shadow of the left thigh musculature is moderately decreased.

RADIOGRAPHIC DIAGNOSIS

- Moderate degenerative osteoarthritis left stifle joint
- Moderate articular swelling left stifle joint
- Disuse atrophy left thigh musculature

INTERPRETATION OF THE FINDINGS & FURTHER RECOMMENDATIONS

The radiographic study is consistent with left sided chronic degenerative osteoarthritis with concomitant joint effusion of the stifle joint. The most-likely underlying cause is (partial) rupture of the cranial cruciate ligament with or without meniscal disease.

A positive drawer sign or tibial compression test under general anesthesia can be used to confirm the diagnosis.



PATIENT

Mason Lewis

SPECIES

Canine

BREED

Havanese Mix

SEX

Male Neutered

AGE

5 Years

INTERPRETED BY

Sebastian Schaub, DVM
Dr. med. vet. DipECVDI

HOSPITAL NAME

The Pet Hospital of
Stratford

REFERRING VET

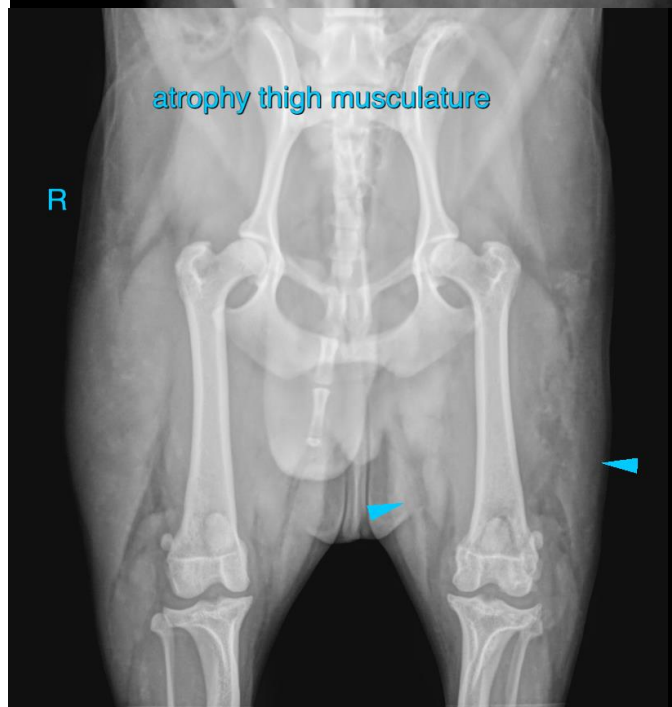
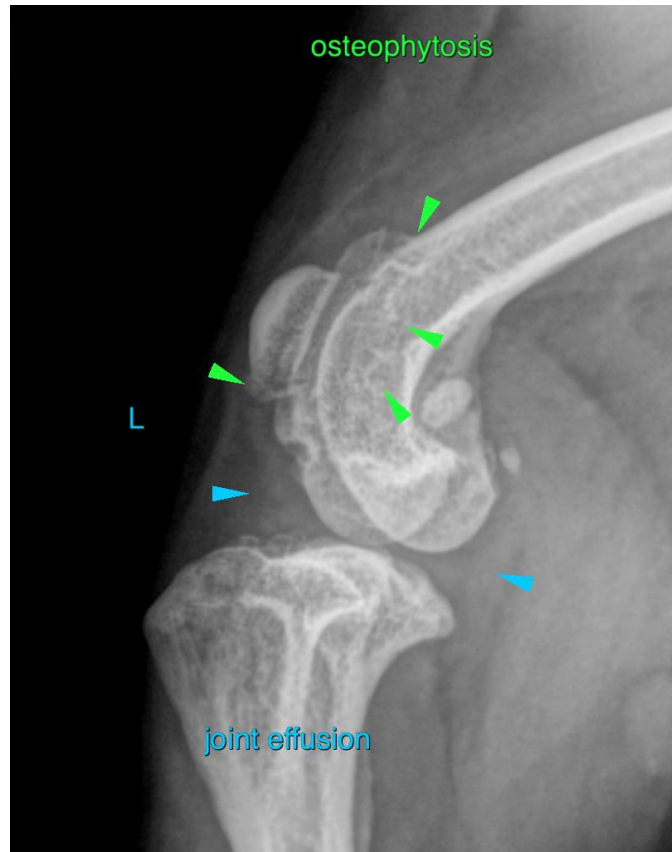
Dr. Claudia Giuliani

INVOICE

53387

DATE

8-10-22





PATIENT

Mason Lewis

The information and recommendations provided are based on the images presented by the referring veterinarian/sonographer. No evaluation can be communicated regarding pathology that was not visible in the image/video clips provided.

SPECIES

Canine

Thank you for this referral. If the clinical or image interpretation does not parallel your findings or if I can be of any further assistance please contact me.

Sebastian Schaub, Sebastian Schaub, DVM, Dr. med. vet. DipECVDI
sebast.schaub@gmail.com

BREED

Havanese Mix

SEX

Male Neutered

AGE

5 Years

INTERPRETED BY

Sebastian Schaub, DVM
Dr. med. vet. DipECVDI

HOSPITAL NAME

The Pet Hospital of
Stratford

REFERRING VET

Dr. Claudia Giuliani

INVOICE

53387

DATE

8-10-22