



**PATIENT**

Maisy Rodenbaugh

**PRESENTING CLINICAL SIGNS**

Came in last year for limping right hind and owner couldn't afford surgery. Now she is back a year later for recheck xrays and is wanting to pursue surgery.

Abnormal PE/Chem/CBC/UA Results: DECREASED MUSCLE MASS AND CREPITUS IN RIGHT HIND LEG(arthritis)

**SPECIES**

Canine

**RADIOGRAPHIC STUDY OF THE STIFLE JOINTS**

Radiographs of the stifle joints in two orthogonal imaging planes are provided for review.

**BREED**

Terrier Mix

**RADIOGRAPHIC FINDINGS**

The left stifle joint presents smooth osseous margins and no signs of intracapsular soft tissue swelling.

**SEX**

FS

The periarticular bones of the right stifle joint present moderate osteophyte new bone formation and a moderate intracapsular soft tissue swelling is appreciated.

The volume of the soft tissue shadow of the right thigh musculature is moderately decreased.

**AGE**

8 Years, 7 Months

**RADIOGRAPHIC DIAGNOSIS**

- Degenerative osteoarthritis right stifle joint
- Moderate articular swelling right stifle joint
- Disuse atrophy musculature right hind limb
- Normal left stifle joint

**INTERPRETED BY**

Sebastian Schaub, DVM  
Dr. med. vet. DipECVDI

**INTERPRETATION OF THE FINDINGS & FURTHER RECOMMENDATIONS**

The radiographic study is consistent with right sided chronic degenerative osteoarthritis with concomitant joint effusion of the stifle joint. The most-likely underlying cause is (partial) rupture of the cranial cruciate ligament with or without meniscal disease.

**HOSPITAL NAME**

Elizabeth Animal  
Hospital

A positive drawer sign or tibial compression test under general anesthesia can be used to confirm the diagnosis.

**REFERRING VET**

Kim Allyn, DVM

**INVOICE**

53382

**DATE**

8-10-22



**PATIENT**

Maisy Rodenbaugh

**SPECIES**

Canine

**BREED**

Terrier Mix

**SEX**

FS

**AGE**

8 Years, 7 Months

**INTERPRETED BY**

Sebastian Schaub, DVM  
Dr. med. vet. DipECVDI

**HOSPITAL NAME**

Elizabeth Animal  
Hospital

**REFERRING VET**

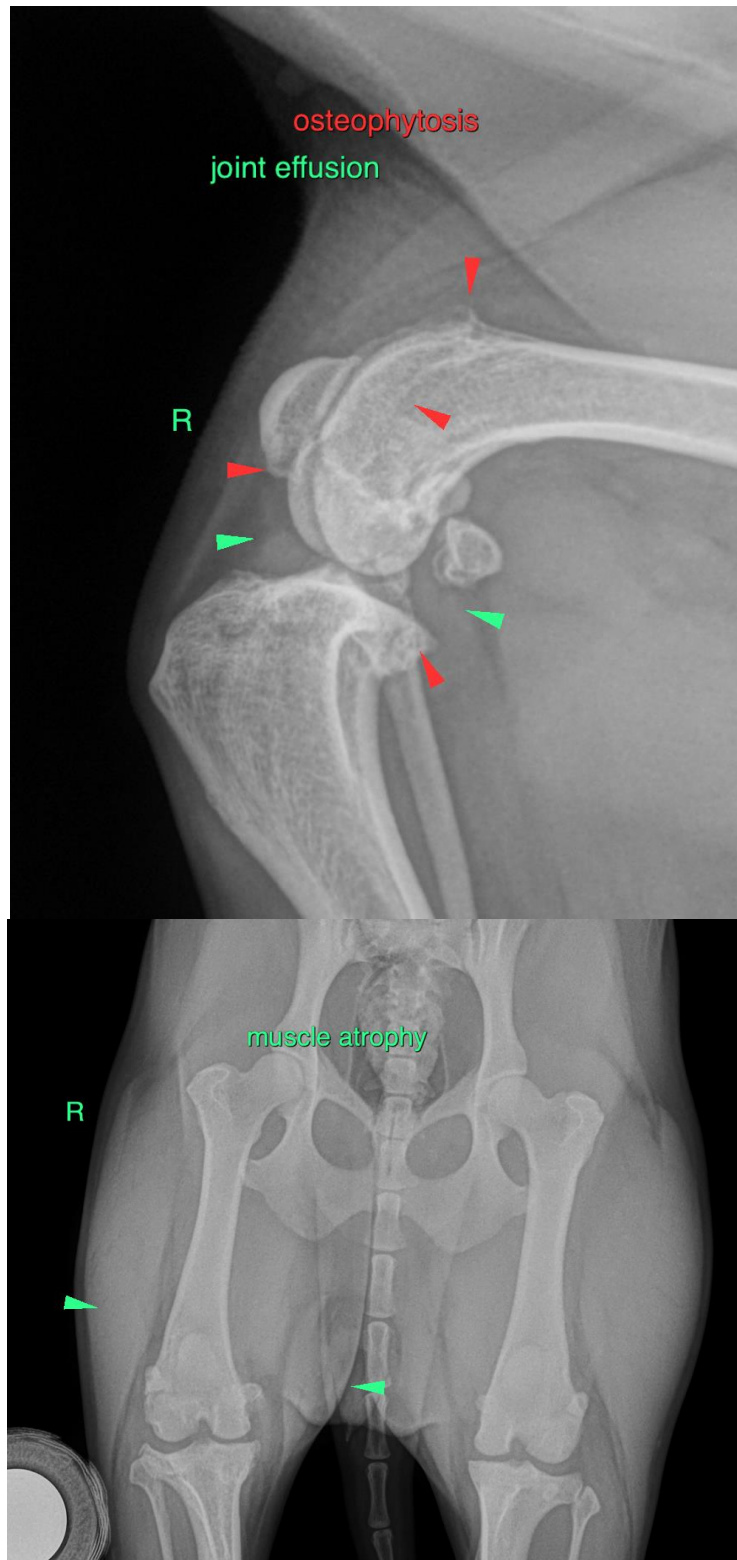
Kim Allyn, DVM

**INVOICE**

53382

**DATE**

8-10-22





**PATIENT**

Maisy Rodenbaugh

**SPECIES**

Canine

**BREED**

Terrier Mix

**SEX**

FS

**AGE**

8 Years, 7 Months

**INTERPRETED BY**

Sebastian Schaub, DVM  
Dr. med. vet. DipECVDI

**HOSPITAL NAME**

Elizabeth Animal  
Hospital

**REFERRING VET**

Kim Allyn, DVM

**INVOICE**

53382

**DATE**

8-10-22

The information and recommendations provided are based on the images presented by the referring veterinarian/sonographer. No evaluation can be communicated regarding pathology that was not visible in the image/video clips provided.

Thank you for this referral. If the clinical or image interpretation does not parallel your findings or if I can be of any further assistance please contact me.

**Sebastian Schaub**, Sebastian Schaub, DVM, Dr. med. vet. DipECVDI  
sebast.schaub@gmail.com