



PATIENT

Colby Jack Dauster

PRESENTING CLINICAL SIGNS

Patient has been very painful in mouth, was difficult to open mouth during examination. Does not appear to have stomatitis. Suspect FOPS.

SPECIES

Feline

COMPUTED TOMOGRAPHY OF THE SKULL

A high resolution pre- and post-contrast CT study of the skull is provided for review.

BREED

DSH

COMPUTED TOMOGRAPHIC FINDINGS

Triadan 109, 204, 206, 301, 401 and 407-409 are absent, moderate atrophy of the alveolar bone of the right mandible is appreciated. Small remaining fragments of triadan 301&401 are appreciated within the alveolar bone.

SEX

Male Neutered

A mild amount of fluid attenuating material is attached to the nasal mucosal lining of the right nasal cavity.

Both temporomandibular joints present congruent joint spaces with even subchondral bone surfaces and are considered within normal limits.

AGE

13 Years

Both tympanic bullae are aerated, the mucosal lining is not seen, the bony wall is smooth and thin. The external ear canals are within normal limits.

The brain presents no deviation from normal anatomy and symmetry. The brain parenchyma is homogeneous and within normal limits for attenuation and distribution of contrast enhancement. The ventricular system is non-dilated and symmetric.

INTERPRETED BY

Sebastian Schaub, DVM
Dr. med. vet. DipECVDI

The mandibular lymph nodes are prominent.

COMPUTED TOMOGRAPHIC DIAGNOSIS

- Lymphadenopathy mandibular lymph nodes
- Mild rhinitis
- Absent triadan 109, 204, 206, 301, 401 and 407-409

HOSPITAL NAME

Scottsdale Veterinary
Clinic

INTERPRETATION OF THE FINDINGS & FURTHER RECOMMENDATIONS

The CT study presents without abnormalities, explaining the described clinical signs. The prominent mandibular lymph nodes are suggestive for reactive hyperplasia, recommend FNA sampling to confirm the diagnosis and ruling out malignant transformation.

REFERRING VET

Dr. D'Monte

INVOICE

53395

DATE

8-10-22



PATIENT

Colby Jack Dauster

SPECIES

Feline

BREED

DSH

SEX

Male Neutered

AGE

13 Years

INTERPRETED BY

Sebastian Schaub, DVM
Dr. med. vet. DipECVDI

HOSPITAL NAME

Scottsdale Veterinary
Clinic

REFERRING VET

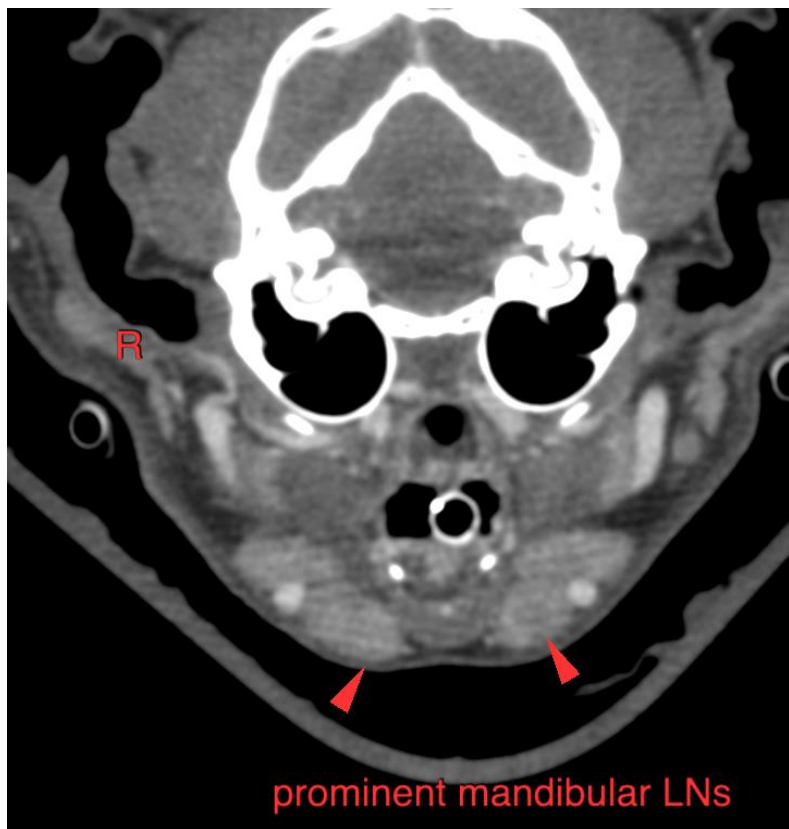
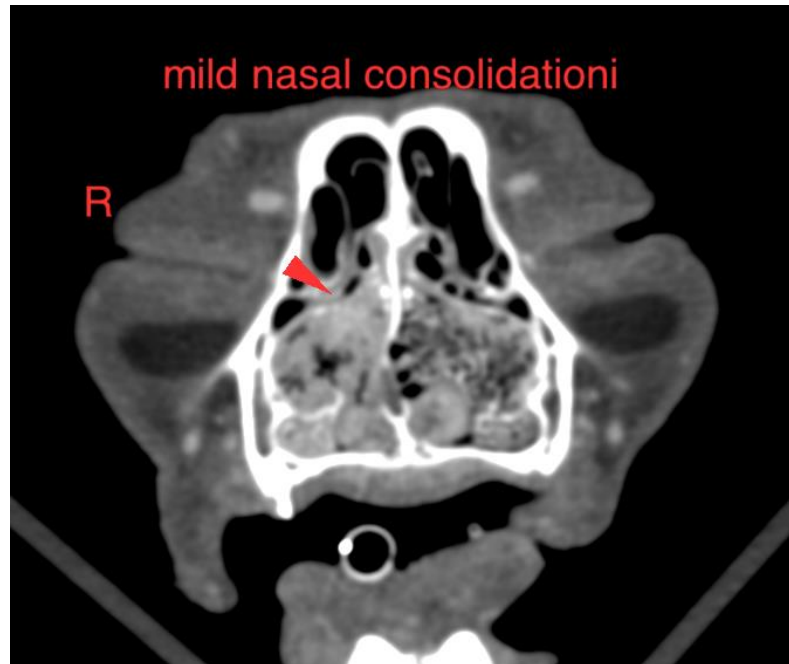
Dr. D'Monte

INVOICE

53395

DATE

8-10-22





PATIENT

Colby Jack Dauster

The information and recommendations provided are based on the images presented by the referring veterinarian/sonographer. No evaluation can be communicated regarding pathology that was not visible in the image/video clips provided.

SPECIES

Feline

Thank you for this referral. If the clinical or image interpretation does not parallel your findings or if I can be of any further assistance please contact me.

BREED

DSH

Sebastian Schaub, Sebastian Schaub, DVM, Dr. med. vet. DipECVDI
sebast.schaub@gmail.com

SEX

Male Neutered

AGE

13 Years

INTERPRETED BY

Sebastian Schaub, DVM
Dr. med. vet. DipECVDI

HOSPITAL NAME

Scottsdale Veterinary
Clinic

REFERRING VET

Dr. D'Monte

INVOICE

53395

DATE

8-10-22