

**PATIENT PRESENTING CLINICAL SIGNS**

Chewy Rodriguez Acute paraparesis

COMPUTED TOMOGRAPHY OF THE THORACIC & LUMBAR SPINE**SPECIES** A high resolution plain and myelographic CT study of the thoracic & lumbar spine is provided for review.Canine **COMPUTED TOMOGRAPHIC FINDINGS****BREED** THE LAST RIB BEARING VERTEBRA IS COUNTED AS T14 – THE RIBS ARE FUSED TO THE RESPECTIVE VERTEBRA – ONLY 6 lumbar vertebra are appreciated.

French Bulldog T8 & T12 present as hemivertebra.

SEX The intervertebral disc space L1/L2 is moderately narrowed and presents a small central vacuum phenomenon, mild hyperattenuating material is seen in the right lateral aspect of the vertebral canal, occupying approximately up to 40% of the cross-sectional area of the vertebral canal at the same level. The mild hyperattenuating material is extending cranially over the complete length of the vertebral body of L2 caudally and approximately up to the mid segment of the vertebral body of L1.. The spinal cord at the same level is displaced to the left and compressed.

Intact Male

AGE Level with the intervertebral disc space T13/T14 and T14/L1 mild mineralized disc material is protruding into the vertebral canal.

3 years The intervertebral disc L6/S1 is protruding into the left aspect of the vertebral canal and the respective neuroforamen, a vacuum phenomenon is seen within the respective intervertebral disc space.

INTERPRETED BY COMPUTED TOMOGRAPHIC DIAGNOSISSebastian Schaub, DVM
Dr. med. vet. DipECVDI

- Intervertebral disc extrusion L1/L2 with compressive myelopathy
- Degenerative lumbosacral stenosis with left sided neuroforaminal stenosis
- Mild intervertebral disc protrusion T13/T14 & T14/L1
- Thoracolumbar transitional vertebra (14 thoracic and 6 lumbar vertebra)
- Hemivertebra T8 & T12
- Spondylosis deformans

HOSPITAL NAME

Mobile Pet Imaging

REFERRING VET INTERPRETATION OF THE FINDINGS & FURTHER RECOMMENDATIONS

Meaux The intervertebral disc extrusion L1/L2 from the right is explaining the presenting clinical signs and surgical decompression is advised.

INVOICE

53408

DATE

8-10-22



PATIENT

Chewy Rodriguez

SPECIES

Canine

BREED

French Bulldog

SEX

Intact Male

AGE

3 years

INTERPRETED BY

Sebastian Schaub, DVM
Dr. med. vet. DipECVDI

HOSPITAL NAME

Mobile Pet Imaging

REFERRING VET

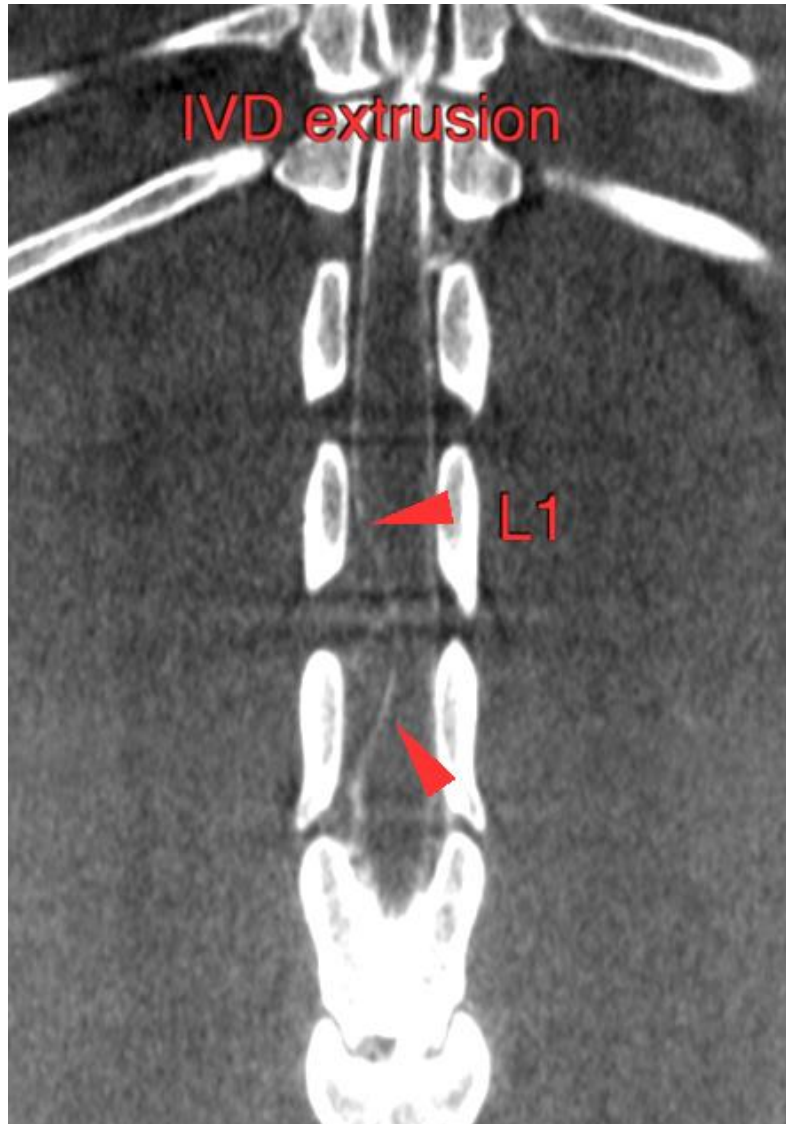
Meaux

INVOICE

53408

DATE

8-10-22





PATIENT

Chewy Rodriguez

SPECIES

Canine

BREED

French Bulldog

SEX

Intact Male

AGE

3 years

INTERPRETED BY

Sebastian Schaub, DVM
Dr. med. vet. DipECVDI

HOSPITAL NAME

Mobile Pet Imaging

REFERRING VET

Meaux

The information and recommendations provided are based on the images presented by the referring veterinarian/sonographer. No evaluation can be communicated regarding pathology that was not visible in the image/video clips provided.

Thank you for this referral. If the clinical or image interpretation does not parallel your findings or if I can be of any further assistance please contact me.

Sebastian Schaub, Sebastian Schaub, DVM, Dr. med. vet. DipECVDI
sebast.schaub@gmail.com

INVOICE

53408

DATE

8-10-22

