



**PATIENT PRESENTING CLINICAL SIGNS**

**PATIENT** Phoebe Markwart  
**SPECIES** History: Phoebe, a 7 mo old Female Labrador Retriever, was presented to the Toronto Animal Health Partners Surgery Service for evaluation of a suspect left OCD hock lesion. At the end of April Phoebe slipped and was NWB on the left hindlimb for a few days. 2-3 weeks ago Phoebe's primary care vet confirmed an OCD lesion on the hock. At the end of the day she becomes much more lame after playing.

Canine Abnormal PE/Chem/CBC/UA Results:

**COMPUTED TOMOGRAPHIC STUDY OF THE TARSAL JOINTS**

**BREED**

Labrador Retriever  
 A plain CT study of the tarsal joints in a soft tissue and bone recon is provided for review.

**COMPUTED TOMOGRAPHIC FINDINGS**

**SEX**

Female  
 The periarticular bones of the left talocrural joint present mild osteophyte new bone formation. A moderate intracapsular soft tissue swelling of the left talocrural joint is present with outpouching of the joint capsule in the plantaroproximal direction.

**AGE**

7 Months 13 Days  
 The distal contour of the medial malleolus presents a crescent shaped irregular defect with an isolated mineralized body distally measuring 7 x 7 x 7 mm in size and smaller isolated mineralized bodies measuring up to 3 mm in size. The medial aspect of the medial trochlear ridge of the calcaneus presents an irregular surface of the bone.

**INTERPRETED BY**

The cortex of the left tibia presents a reduced width in comparison to the contralateral limb.

Sebastian Schaub,  
 DVM Dr. med. vet.  
 DipECVCI

**COMPUTED TOMOGRAPHIC DIAGNOSIS**

- Osteochondrosis dissecans (OCD) of the medial malleolus left tarsal joint
- Moderate articular swelling left talocrural joint
- Mild degenerative osteoarthritis left talocrural joint
- Mild disuse atrophy of the left tibia

**HOSPITAL NAME**

Animal Health Partners

**INTERPRETATION OF THE FINDINGS & FURTHER RECOMMENDATIONS**

**REFERRING VET**

Lea Mehrkens

The findings are suggestive for an OCD lesion of the left medial malleolus with a large mineralized body and multiple small mineralized bodies in the same region with secondary degenerative changes. The large mineralized body would be the result of a potential cartilaginous body being nutrified by the joint capsule. However, as there is a history of potential trauma chronic avulsion fracture level with the insertion of the short medial collateral ligament is a potential but considered less likely. Recommend stressed radiographs of the tarsal joint to check for instability. Removal of the osseous fragments is would be beneficial – although surgical intervention will likely accelerate osteophyte formation.

**INVOICE**

12500

The irregular contour of the medial aspect of the left talus is considered secondary to mechanical interaction with the mineralized bodies.

**DATE**

8/10/21



**PATIENT**

Phoebe Markwart

**SPECIES**

Canine

**BREED**

Labrador Retriever

**SEX**

Female

**AGE**

7 Months 13 Days

**INTERPRETED BY**

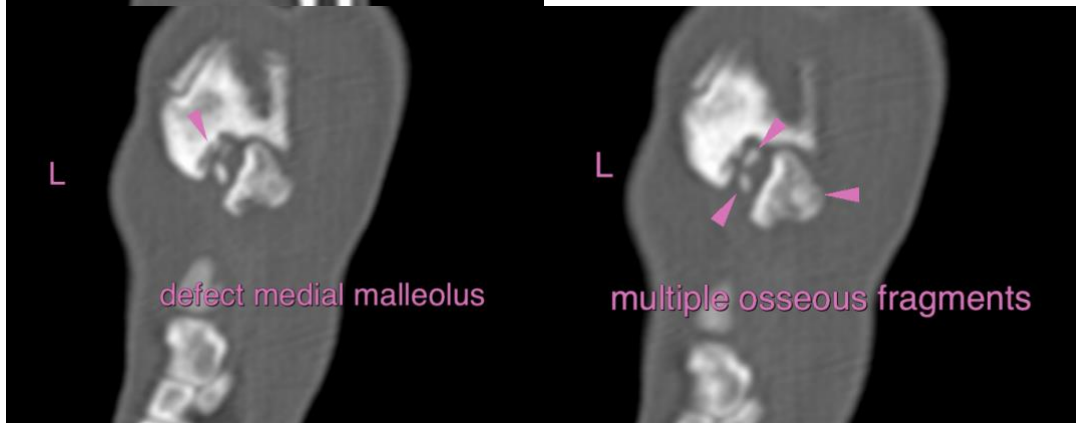
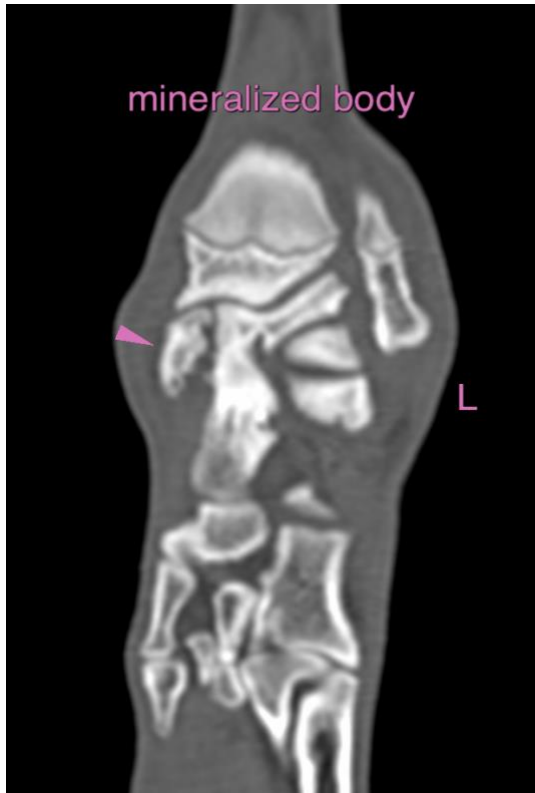Sebastian Schaub,  
DVM Dr. med. vet.  
DipECVDI

**HOSPITAL NAME**

Animal Health  
Partners

**REFERRING VET**

Lea Mehrkens



**INVOICE**

12500

**DATE**

8/10/21

The information and recommendations provided are based on the images presented by the referring veterinarian. No evaluation can be communicated regarding pathology that was not visible in the image/video clips provided.

Thank you for this referral. If the clinical or image interpretation does not parallel your findings or if



**PATIENT** I can be of any further assistance please contact me.

Phoebe Markwart **Sebastian Schaub**, Sebastian Schaub, DVM, Dr. med. vet. DipECVDI  
sebast.schaub@gmail.com

**SPECIES**

Canine

**BREED**

Labrador Retriever

**SEX**

Female

**AGE**

7 Months 13 Days

**INTERPRETED BY**

Sebastian Schaub,  
DVM Dr. med. vet.  
DipECVDI

**HOSPITAL NAME**

Animal Health  
Partners

**REFERRING VET**

Lea Mehrkens

**INVOICE**

12500

**DATE**

8/10/21