



**PATIENT PRESENTING CLINICAL SIGNS**

King Chernack History: King presented for evaluation of cervical mass that was diagnosed possible thyroid carcinoma by FNA.

**SPECIES Abnormal PE/Chem/CBC/UA Results:**

Canine **COMPUTED TOMOGRAPHIC STUDY OF THE SKULL & NECK**

A high resolution post-contrast CT study of the skull including the neck is provided for review.

**BREED COMPUTED TOMOGRAPHIC FINDINGS**

Golden Retriever  
The tooth element 308 is absent.

**SEX** The nasal cavity presents the expected aerated spaces between thin and even conchae and turbinates with smooth mucosal lining.

Neutered Male

Both temporomandibular joints present congruent joint spaces with even subchondral bone surfaces and are considered within normal limits.

**AGE**

11 Years

Both tympanic bullae are aerated, the mucosal lining is not seen, the bony wall is smooth and thin. The right external ear canal is mildly narrowed and in the most medial aspect a mild amount of soft tissue attenuating material is visible in the lumen of the right external ear canal.

**INTERPRETED BY**

Sebastian Schaub,  
DVM Dr. med. vet.  
DipECVDI

The brain presents no deviation from normal anatomy and symmetry. The brain parenchyma is homogeneous and within normal limits for attenuation and distribution of contrast enhancement. The ventricular system is non-dilated and symmetric.

The esophagus is moderately distended by fluid – likely secondary to general anesthesia.

**HOSPITAL NAME**

Animal Surgical  
Center

A diffuse generalized moderate to marked soft tissue swelling of all anatomical structures of the larynx is visible presenting a heterogeneous contrast enhancement pattern. The right internal jugular vein, level with the larynx is moderately to markedly dilated, measuring up to 1.5 cm in diameter with central filling defects. Multiple tortuous vessels are seen at the right caudolateral aspect of the larynx.

**REFERRING VET**

Peace Love Pets

The medial retropharyngeal lymph nodes are prominent and elongated with a normal short-to-long-axis-ratio is < 0.5, the contrast enhancement pattern is mildly irregular.

The thyroid glands cannot be delineated bilaterally.

**INVOICE COMPUTED TOMOGRAPHIC DIAGNOSIS**

12501

- Intramural mass of the larynx with vascular invasion of the internal jugular vein
- Mild lymphadenopathy medial retropharyngeal lymph nodes

**DATE**

8/10/21



**PATIENT**

- Absent tooth element 308

King Chernack

**INTERPRETATION OF THE FINDINGS & FURTHER RECOMMENDATIONS**

**SPECIES**

Canine

There is a diffuse intramural mass originating from the larynx with vascular invasion. The organ of origin cannot be defined and primary laryngeal mass (e.g. lymphosarcoma, squamous cell carcinoma) as well as infiltrative growing perilaryngeal mass (e.g. thyroid carcinoma) are considerations here. Due to the involvement of the complete larynx, there are no surgical treatment options. Based on the results of the advanced diagnostic tests, the chances of chemotherapy can be discussed with oncologist. Progressive growth can result in dyspnea.

**BREED**

Golden Retriever

The prominent medial retropharyngeal lymph nodes can indicate reactive hyperplasia versus metastatic spread, recommend FNA sampling as next diagnostic step.

Consider full tumor staging.

**SEX**

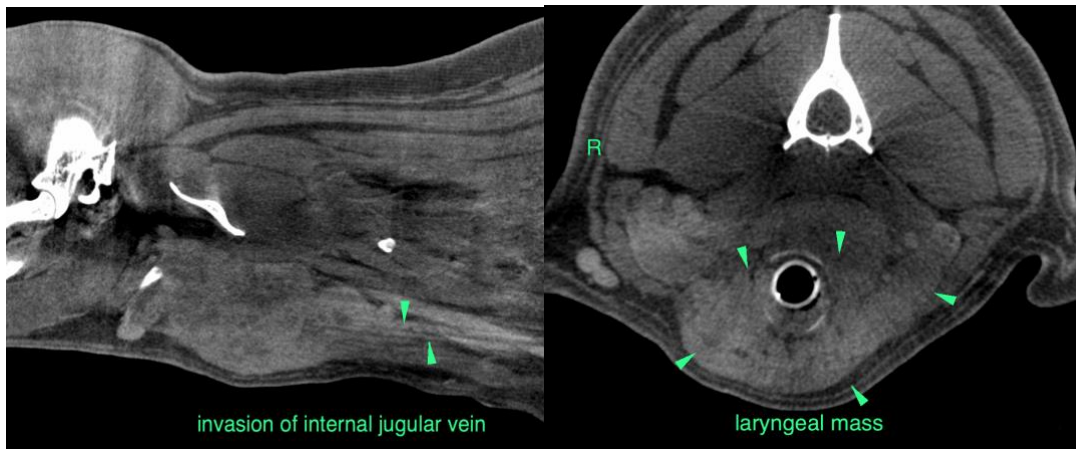
Neutered Male

**AGE**

11 Years

**INTERPRETED BY**

Sebastian Schaub,  
DVM Dr. med. vet.  
DipECVDI



**HOSPITAL NAME**

Animal Surgical  
Center

**The information and recommendations provided are based on the images presented by the referring veterinarian. No evaluation can be communicated regarding pathology that was not visible in the image/video clips provided.**

**REFERRING VET**

Peace Love Pets

Thank you for this referral. If the clinical or image interpretation does not parallel your findings or if I can be of any further assistance please contact me.

**Sebastian Schaub**, Sebastian Schaub, DVM, Dr. med. vet. DipECVDI  
sebast.schaub@gmail.com

**INVOICE**

12501

**DATE**

8/10/21



**PATIENT**

King Chernack

**SPECIES**

Canine

**BREED**

Golden Retriever

**SEX**

Neutered Male

**AGE**

11 Years

**INTERPRETED BY**

Sebastian Schaub,  
DVM Dr. med. vet.  
DipECVDI

**HOSPITAL NAME**

Animal Surgical  
Center

**REFERRING VET**

Peace Love Pets

**INVOICE**

12501

**DATE**

8/10/21