



PATIENT PRESENTING CLINICAL SIGNS

Maude Kaufmann Intermittent RHL Lameness. Ambulatory x 4 with no obvious lameness seen in consult. No swelling or effusion. Negative cranial drawer and negative tibial thrust on RHL. Subjectively mild medial buttressin

SPECIES RADIOGRAPHIC STUDY OF THE STIFLE JOINTS

Canine Radiographs of the stifle joints in two orthogonal imaging planes are provided for review.

RADIOGRAPHIC FINDINGS

BREED Both stifle joints have smooth margins of the periarticular bones. The patella of both stifle joints is in situ. In comparison to the left stifle joint, the right stifle joint presents a mild intracapsular soft tissue swelling. The tibial plateau angle is increased.

Chihuahua Mix

RADIOGRAPHIC DIAGNOSIS

- Mild articular swelling right stifle joint

Female Spayed

INTERPRETATION OF THE FINDINGS & FURTHER RECOMMENDATIONS

The mild articular swelling of the right stifle joint can be traumatic, degenerative or inflammatory in origin – the most common cause would be pathology of the cranial cruciate ligament ± meniscal disease. Due to the mild clinical signs, a clinical course with rest and NSAID appears beneficial and reevaluating the patient in 3-4 weeks.

AGE

1 Year, 8 Months

INTERPRETED BY

Sebastian Schaub, DVM
Dr. med. vet. DipECVDI

HOSPITAL NAME

DTLAvets

REFERRING VET

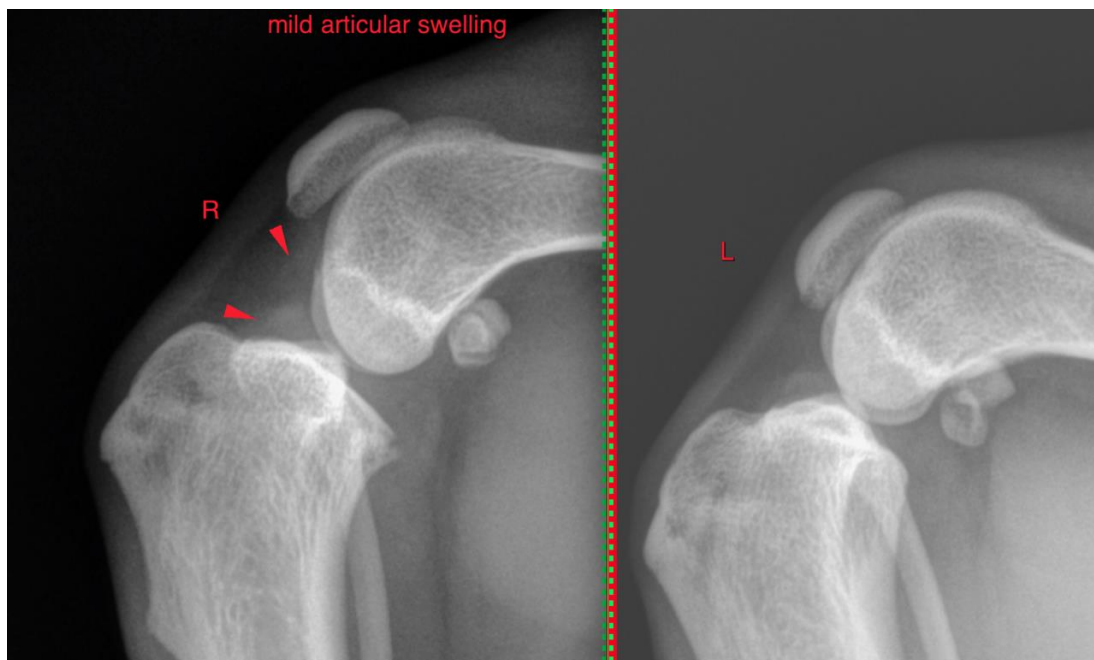
Dr. Coward

INVOICE

59607

DATE

8-1-23





PATIENT The information and recommendations provided are based on the images presented by the referring veterinarian/sonographer. No evaluation can be communicated regarding pathology that was not visible in the image/video clips provided.

Maude Kaufmann

Thank you for this referral. If the clinical or image interpretation does not parallel your findings or if I can be of any further assistance please contact me.

SPECIES

Canine

Sebastian Schaub, Sebastian Schaub, DVM, Dr. med. vet. DipECVDI
info@sonopath.com

BREED

Chihuahua Mix

SEX

Female Spayed

AGE

1 Year, 8 Months

INTERPRETED BY

Sebastian Schaub, DVM
Dr. med. vet. DipECVDI

HOSPITAL NAME

DTLAvets

REFERRING VET

Dr. Coward

INVOICE

59607

DATE

8-1-23