



PATIENT PRESENTING CLINICAL SIGNS

Luna Holt recently diagnosed with chf

RADIOGRAPHIC STUDY OF THE THORAX

SPECIES

Radiographs of the thorax in three imaging planes are provided for review. Images are provided in JPEG file format.

Canine

RADIOGRAPHIC FINDINGS

BREED

The surrounding bony structures are within normal limits.

Chihuahua & Yorkie

The extrathoracic soft tissues present homogeneous without abnormalities.

SEX

The caudal contour of the cardiac silhouette is steep and the caudal cardiac waist is lost. A wedge shaped soft tissue opacity is seen in the region of the left atrium. The pulmonary vasculature is within normal limits.

Female Spayed

The cranial mediastinum presents the expected soft tissue opacity. The mediastinal width is less than twice the width of the vertebral column at the same level.

AGE

12 Years

The included cervical segment of the trachea is moderately dorsoventrally flattened.

The bronchial tree presents with thin walls and tapers uniformly towards the periphery as expected.

INTERPRETED BY

The lung parenchyma presents the expected architecture and opacity; the intrapulmonary vascular branching is seen up to the third order lung vessels.

Sebastian Schaub, DVM
Dr. med. vet. DipECVDI

The diaphragm is well delineated with even surface and the expected mild cranial bulging of the diaphragmatic cupola.

RADIOGRAPHIC DIAGNOSIS

HOSPITAL NAME

Mt. Yonah Animal
Hospital

- Tracheal collapse cervical tracheal segment
- Left sided cardiomegaly without signs of decompensation

INTERPRETATION OF THE FINDINGS & FURTHER RECOMMENDATIONS

REFERRING VET

The most likely underlying cause for the left sided cardiomegaly is mitral valve disease. At this point there is no sign of decompensation. A cardiac echo is considered beneficial for further assessment of cardiac chamber size and function.

Courtney Erwin, DVM

INVOICE

59606

DATE

8-1-23



PATIENT

Luna Holt

SPECIES

Canine

BREED

Chihuahua & Yorkie

SEX

Female Spayed

AGE

12 Years

INTERPRETED BY

Sebastian Schaub, DVM
Dr. med. vet. DipECVDI

HOSPITAL NAME

Mt. Yonah Animal
Hospital

REFERRING VET

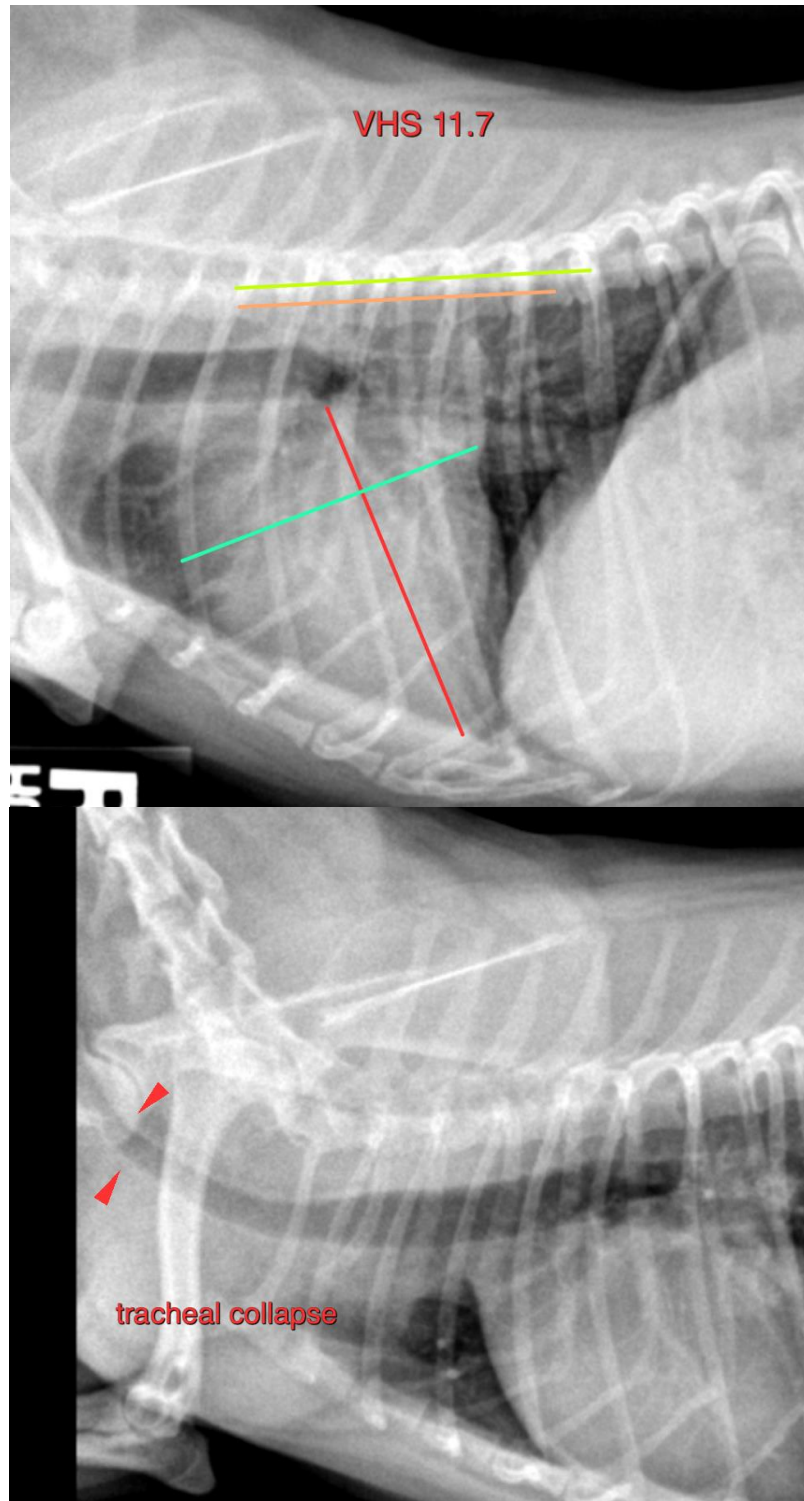
Courtney Erwin, DVM

INVOICE

59606

DATE

8-1-23





PATIENT

Luna Holt **The information and recommendations provided are based on the images presented by the referring veterinarian/sonographer. No evaluation can be communicated regarding pathology that was not visible in the image/video clips provided.**

SPECIES

Canine

Thank you for this referral. If the clinical or image interpretation does not parallel your findings or if I can be of any further assistance please contact me.

BREED

Chihuahua & Yorkie

Sebastian Schaub, Sebastian Schaub, DVM, Dr. med. vet. DipECVDI
info@sonopath.com

SEX

Female Spayed

AGE

12 Years

INTERPRETED BY

Sebastian Schaub, DVM
Dr. med. vet. DipECVDI

HOSPITAL NAME

Mt. Yonah Animal
Hospital

REFERRING VET

Courtney Erwin, DVM

INVOICE

59606

DATE

8-1-23