



**PATIENT PRESENTING CLINICAL SIGNS**

Phoebe Hamada

8/1/22 - 14 mo Post RT: Phoebe has been doing very well. Eating and drinking well. Breathing well. No concerns. Current Medication: Joint supplement, dietary supplement Appetite and Activity: Both good 1/18/22 - 7 Month Post RT: The CT findings show that the left thyroid carcinoma has reduced in size significantly since the first dose of radiation therapy was given on 5/26/21. On 5/6/21 the mass in the coronal plane measured 60.0 x 3.5 mm (current 35.4 x 19.5 mm), sagittal plane 63.7 x 37.7 mm (current 41.0 x 25.0 mm) and transverse 35.7 x 37.1 mm (current 25.7 x 18.1 mm). There is no visible mass within the lumen of the larynx or distal trachea. It appears there is stable disease at this time. The CT radiologist report confirms reduction the size of the left thyroid mass compared to pre radiation therapy. The mass appears to still invade the wall of the larynx and esophagus. There is no evidence of metastatic disease to lymph nodes or lungs at this time. 9/27/21 - 3 Month Post RT: The left thyroid mass is reducing in size. There is thickening palpable in the left ventral neck but a well defined mass is not easily discerned. She is breathing well without any evidence of laryngeal obstruction. Contrast CT of the neck shows the mass is reduced in size compared to pre radiation therapy. Margins of the mass are contrast enhanced and the center is non contrast enhancing supportive of reduced blood supply or necrotic tissue. The endoscopy findings of the larynx show there is no recurrence of the mass within the laryngeal lumen and the mucosa has healed well. The original size of the left thyroid mass was 74 mm in length x 30 mm in width x 34 mm in height. Now the mass measures 41 mm in length x 19.7 mm in width x 19.2 mm in height. 6/24/21 - HDR Brachytherapy: The owner reports that Phoebe is doing okay. Her appetite and energy levels are good. She still has a cough. Sometimes her bark sounds different. The thyroid carcinoma is reduced in size compared to last month. The mass measured 74 mm in length x 30 mm in width x 34 mm in height last month. The mass now measures 50.1 mm in length x 26.8 mm in height x 32 mm in width. Mass tissue within the larynx has receded and appears to be healing well. The mass deep to the left vocal fold is also reduced in size compared to last month. She appears to be responding to the initial dose of radiation therapy. A dose of 12 Gy was delivered today. 5/26/21 - HDR Brachytherapy: She was much improved after the laryngeal mass debulking procedure and was able to breathe more freely. Appetite and activity have been normal. She does cough some in the morning. She is not acting painful. The owner reports that her breathing has become labored in the last few days, her bark has changed and she has had reduced energy for the last 2 days. The mass within the lumen of the larynx has grown a small amount compared to post debulking 1 month ago. There is also mass tissue beneath the left vocal fold that appears to be larger than before. The mass beneath the vocal fold appears to cause some airway obstruction. The lumen of the larynx remains patent. A dose 12 Gy is delivered to the thyroid carcinoma. Good margins and coverage are obtained. A second dose of radiation therapy is recommended in 1 month. Carprofen and clindamycin are dispensed. Drainage from the catheter sites may persist for several days and should be wiped away with a wet cloth to keep her neck clean. 4/29/21 - CT/Bronchoscopy: CT and bronchoscopy findings document the presence of a large mass arising from the area of the left thyroid gland. Biopsies confirm a thyroid carcinoma. The carcinoma is invasive and has eroded through the wall of the larynx and proximal trachea, esophagus and carotid artery. There was no evidence of enlarged cervical lymph nodes or pulmonary masses or nodules. The mass within the laryngeal lumen causing airway obstruction was resected for palliation using a Coblation wand. Abnormal PE/Chem/CBC/UA Results: PE: The left thyroid mass is difficult to palpate; no stridor; breathes normally Lab: Blood work is dated 6/21/22. CBC - PCV = 48%, WBC = 7200, neutrophils = 4752, lymphocytes = 1368, monocytes = 792. Platelets = 219,000. Chemistry - normal. Urinalysis - not provided. Laryngoscopy: The endoscopic appearance of the larynx has not changed compared to images obtained 6 months ago. There is mild displacement of the left laryngeal wall medially. The mucosal surface of the left laryngeal wall is mildly irregular with multiple small focal areas of hyperemia and petechial hemorrhages. The left vocal fold is mildly

**SPECIES**

Canine

**BREED**

Mini Aussie

**SEX**

SF

**AGE**

9 Years

**INTERPRETED BY**

Sebastian Schaub, DVM  
Dr. med. vet. DipECVDI

**HOSPITAL NAME**

VetMed Consultants

**REFERRING VET**

Kanda Hazelwood

**INVOICE**

53194

**DATE**

8-1-22



**PATIENT** thickened and irregular. Mass tissue does not protrude into the laryngeal lumen.

Phoebe Hamada

**COMPUTED TOMOGRAPHY OF THE NECK AND THORAX**

A high resolution pre- and post-contrast CT study of the neck and a plain CT study of the thorax are provided for review.

**SPECIES**

Canine

**COMPUTED TOMOGRAPHIC FINDINGS**

Neck

Originating from the left thyroid gland, an ill-defined, soft tissue attenuating and heterogeneous strong contrast enhancing ovoidal mass is seen, measuring 2.6 x 2.0 x 4.0 cm in size – the size is mildly decreased in comparison to the preceding CT study. The medial margins of the mass are stationary blending with the larynx and esophageal wall at the same level. The left vocal fold is swollen and has a mild heterogeneous contrast enhancement pattern.

**BREED**

Mini Aussie

**SEX**

SF

The remainder of the osseous and soft tissue structures of the neck are within normal limits.

Thorax

Multifocal mild spondylosis formation is seen along the caudal thoracic spine.

**AGE**

9 Years

The sternal, cranial mediastinal and tracheobronchial lymph nodes are small elongated with a normal short-to-long-axis-ratio is < 0.5, the attenuation and contrast enhancement pattern is uniform and considered within normal limits.

**INTERPRETED BY**

Sebastian Schaub, DVM  
Dr. med. vet. DipECVDI

The cardiovascular structures including the pulmonary vasculature are within normal limits.

The bronchial tree presents with regular branching and tapers uniformly towards the periphery as expected, the bronchial walls are thin and smooth. The bronchus-to-artery ratio is within normal limits.

**HOSPITAL NAME**

VetMed Consultants

The caudal lung lobes present with multiple, well-defined, soft tissue attenuating nodular lesions, measuring up to 2 mm in diameter – not appreciated in the preceding CT study of the thorax.

Small incidental gas pockets are seen within the esophageal lumen, there is no evidence of abnormal dilation.

**REFERRING VET**

Kanda Hazelwood

**COMPUTED TOMOGRAPHIC DIAGNOSIS**

- History of left sided thyroid carcinoma with local invasive growth, invading the tracheal wall/larynx and esophageal wall – stationary
- Structured nodular interstitial lung pattern
- Spondylosis deformans

**INVOICE**

53194

**INTERPRETATION OF THE FINDINGS & FURTHER RECOMMENDATIONS**

The findings of the left thyroid mass are stationary in comparison to the previous CT study.

**DATE**

8-1-22

There is a developing nodular pattern of the lung parenchyma, highly suggestive for pulmonary metastatic disease.



**PATIENT**

Phoebe Hamada

**SPECIES**

Canine

**BREED**

Mini Aussie

**SEX**

SF

**AGE**

9 Years

**INTERPRETED BY**

Sebastian Schaub, DVM  
Dr. med. vet. DipECVDI

**HOSPITAL NAME**

VetMed Consultants

**REFERRING VET**

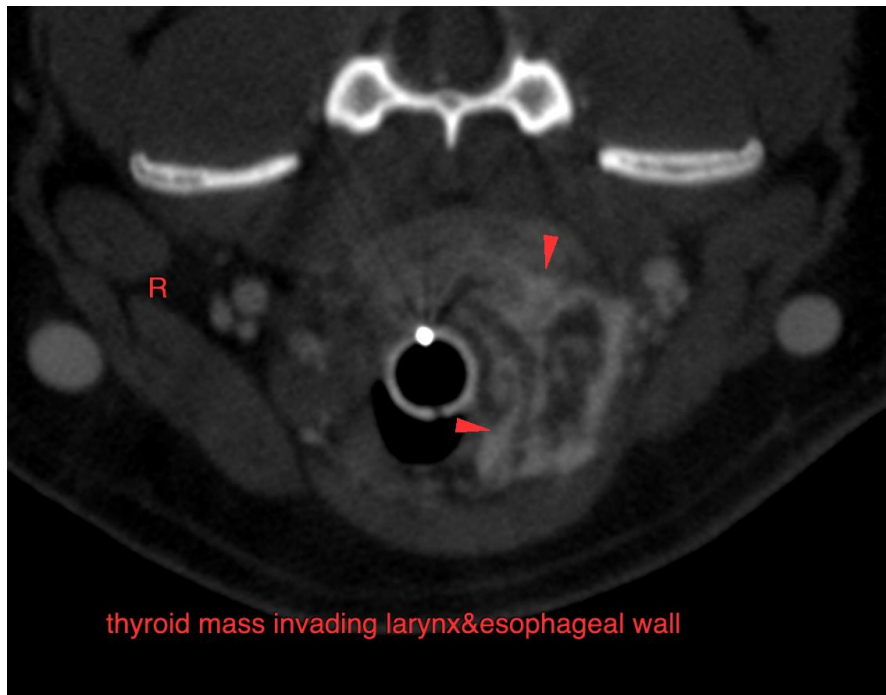
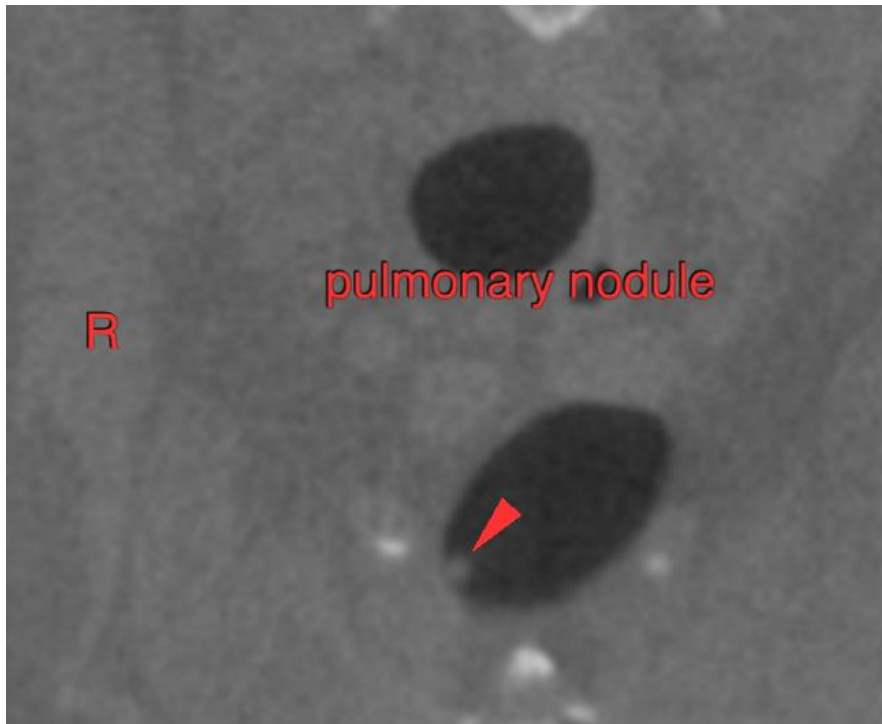
Kanda Hazelwood

**INVOICE**

53194

**DATE**

8-1-22





**PATIENT**

Phoebe Hamada

**SPECIES**

Canine

**BREED**

Mini Aussie

**SEX**

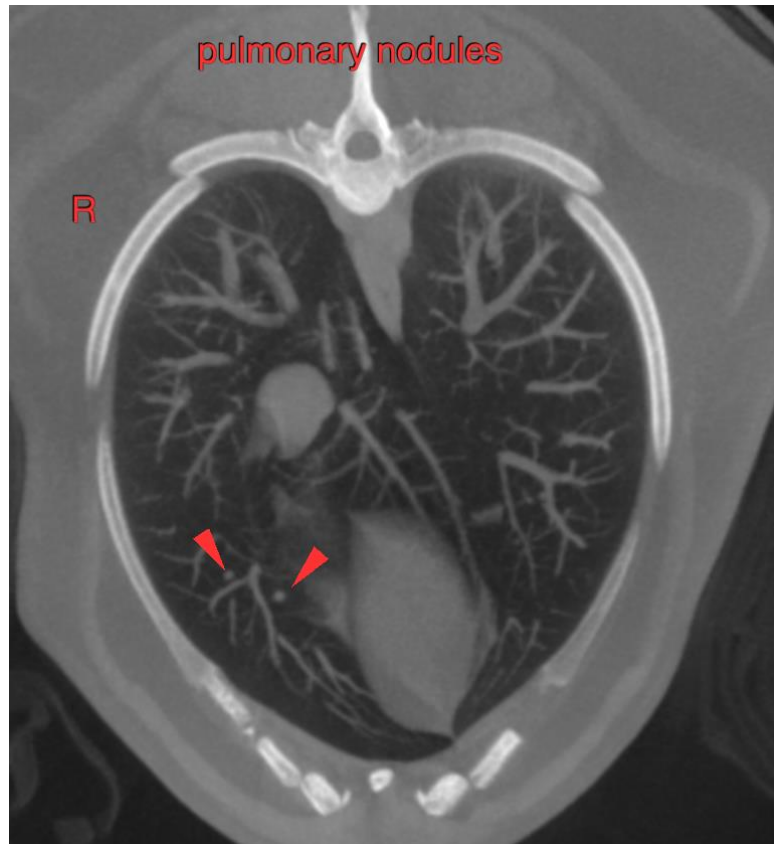
SF

**AGE**

9 Years

**INTERPRETED BY**

Sebastian Schaub, DVM  
Dr. med. vet. DipECVDI



**HOSPITAL NAME**

VetMed Consultants

**REFERRING VET**

Kanda Hazelwood

**INVOICE**

53194

**DATE**

8-1-22

The information and recommendations provided are based on the images presented by the referring veterinarian/sonographer. No evaluation can be communicated regarding pathology that was not visible in the image/video clips provided.

Thank you for this referral. If the clinical or image interpretation does not parallel your findings or if I can be of any further assistance please contact me.

**Sebastian Schaub**, Sebastian Schaub, DVM, Dr. med. vet. DipECVDI  
sebast.schaub@gmail.com