



PATIENT PRESENTING CLINICAL SIGNS

Jasmine Smith
SPECIES Canine
BREED Shepherd Mix
SEX FS
AGE 11 Years
INTERPRETED BY Sebastian Schaub, DVM
 Dr. med. vet. DipECVDI

Jasmine is an 11-year-old, spayed female Shepherd mix who was re-admitted to the hospital on 7/20/22 for continued regurgitation. She had a splenectomy and prophylactic gastropexy performed on 7/8/22 due to a splenic mass that was incidentally found during a lameness workup (bilateral elbow osteoarthritis, R>L) and was not bleeding. The splenic mass came back benign. She also had PRP therapy in both elbows on 7/8/22. She was started on Carprofen on 7/7/22 for arthritis, in addition to the gabapentin she had already been taking. She was discharged on 7/9/22 on Carprofen, Gabapentin, and Omeprazole and had been doing well initially but she started vomiting on 7/11/22 (very dark liquid, coffee grounds). Carprofen was discontinued. She continued eating bland food with a decent appetite but continued to vomit dark fluid. She developed melena on 7/12/22 (formed stool but very dark in color) and was very lethargic at home. She was also coughing intermittently (non-productive). She presented here on 7/13/22 for the vomiting/hematemesis and melena. Full blood work showed mildly elevated BUN, mildly elevated ALP, mildly elevated amylase, moderately elevated lipase, and mild hypokalemia. Coags were normal. Radiographs showed an alveolar pattern in the right middle lung lobe. She was treated in-hospital during the day 7/13 and went home with O that night. She was eating and was improving until 7/15/22 when she stopped eating and started regurgitating again. She was hospitalized again at that time. Repeated thoracic radiographs showed progression of the pneumonia but she was never dependent on oxygen. An NG tube was placed to empty the stomach and it was used to feed her until she started eating on her own. She had not regurgitated in 24 hours and was eating well so she was discharged on the evening of 7/18/22 on oral medication. Upon arriving home, she regurgitated and refused food. On the morning of 7/19/22, she was found trembling and hypersalivating on the bathroom floor. She had diarrhea and regurgitated a large amount and continued to refuse food. An IV catheter was placed at home and she was administered all injectable medications and was on IV fluids at home. She did not continue to regurgitate but continued to refuse all food so she brought back in for re-hospitalization on 7/20/22. Patient was re-explored on 07/22/22 and right sided gastropexy was released.

HOSPITAL NAME COMPUTED TOMOGRAPHY OF THE THORAX AND ABDOMEN

Critical Vet Care/Suncoast Veterinary
 A high resolution pre- and post-contrast CT study of the thorax and abdomen is provided for review.

COMPUTED TOMOGRAPHIC FINDINGS

Thorax

REFERRING VET Multifocal advanced spondylosis formation is seen along the thoracic & lumbar spine.

Dr. Young Both shoulder joints present mild to moderate osteophyte new bone formation. The periarticular bones of the right elbow joint present moderate osteophyte new bone formation.

INVOICE 53187 The right jugular vein, right subclavian vein & axillary vein present with an intraluminal filling defect, occupying approximately up to 75% of the cross-sectional area of the vertebral canal at the same level.

A central venous catheter is seen in the left jugular vein, extending up into the cranial vena cava. Caudal to the tip of the central venous catheter, a mild irregular filling defect is attached to the wall of the cranial vena cava.

DATE

8-1-22



PATIENT

Jasmine Smith

The right axillary & superficial cervical lymph node are prominent and present a heterogeneous contrast enhancement pattern.

The right sternal lymph node is prominent.

SPECIES

Canine

The cardiovascular structures including the pulmonary vasculature are within normal limits.

The bronchial tree presents with regular branching and tapers uniformly towards the periphery as expected, the bronchial walls are thin and smooth. The bronchus-to-artery ratio is within normal limits.

BREED

Shepherd Mix

The lung parenchyma presents the expected architecture and attenuation behavior with interspersed punctuate mineralization.

Small incidental gas pockets are seen within the esophageal lumen, there is no evidence of abnormal dilation.

SEX

FS

Abdomen

A moderate amount of free gas is seen in the peritoneal cavity. The serosal peritoneal fat presents moderate fat-stranding.

AGE

11 Years

Both kidneys present within normal limits for size, shape and organ architecture. After contrast administration a bilaterally symmetric and uniform nephro- and pyelogram is noted.

The adrenal glands are within normal limits for size, shape and organ architecture.

INTERPRETED BY

Sebastian Schaub, DVM
Dr. med. vet. DipECVDI

The liver presents with normal shape, even surface, uniformly attenuating parenchyma and homogeneous contrast enhancement, unremarkable.

The spleen is absent.

The pancreas, especially the corpus and left lobe, is significantly swollen with undulating margins and presents with a hypoattenuating parenchyma post contrast administration.

HOSPITAL NAME

Critical Vet
Care/Suncoast
Veterinary

A gastric tube is visible. The wall of the pyloric antrum is prominent and the respective rugal folds are prominent. The delineation, wall and content of the intestinal tract are considered within normal limits throughout.

The lumbosacral intervertebral disc is moderately protruding into the vertebral canal, occupying approximately up to 50% of the cross-sectional area of the vertebral canal at the same level. Both coxofemoral joints present moderate osteophyte new bone formation.

REFERRING VET

Dr. Young

COMPUTED TOMOGRAPHIC DIAGNOSIS

- Significant swelling of the pancreas
- Lymphadenopathie right sternal, axillary and superficial cervical lymph node
- Thrombus formation right jugular, subclavian and axillary vein – extending distally along the brachial vein
- Small thrombus level with the tip of the central venous catheter in the cranial vena cava
- Suspect gastritis
- History of celiotomy with secondary pneumohydroperitoneum
- Degenerative osteoarthritis elbow joints bilaterally
- Degenerative lumbosacral stenosis with potential dynamic compression of the caudal equina fibers

INVOICE

53187

DATE

8-1-22



PATIENT

Jasmine Smith

- Degenerative osteoarthritis coxofemoral joints bilaterally
- Spondylosis deformans
- Pulmonary osteomas

SPECIES

Canine

BREED

Shepherd Mix

SEX

FS

AGE

11 Years

INTERPRETED BY

Sebastian Schaub, DVM
Dr. med. vet. DipECVDI

HOSPITAL NAME

Critical Vet
Care/Suncoast
Veterinary

REFERRING VET

Dr. Young

INVOICE

53187

DATE

8-1-22

INTERPRETATION OF THE FINDINGS & FURTHER RECOMMENDATIONS

There is significant swelling of the pancreas, the odds for pancreatitis are considered high and can cause prothrombotic state, explaining the thrombus formation in the right jugular, subclavian and axillary/brachial vein. A central venous catheter in the right jugular vein can be a cause for the right sided thrombotic event as well. If not done so yet, recommend complementing blood work by cpl.

The right axillary, cervical superficial, sternal and a cranial mediastinal lymph node are moderately enlarged and reactive hyperplasia or neoplastic transformation (e.g. round cell tumor) need to be differentiated by FNA sampling.



PATIENT

Jasmine Smith

SPECIES

Canine

BREED

Shepherd Mix

SEX

FS

AGE

11 Years

INTERPRETED BY

Sebastian Schaub, DVM
Dr. med. vet. DipECVDI

HOSPITAL NAME

Critical Vet
Care/Suncoast
Veterinary

REFERRING VET

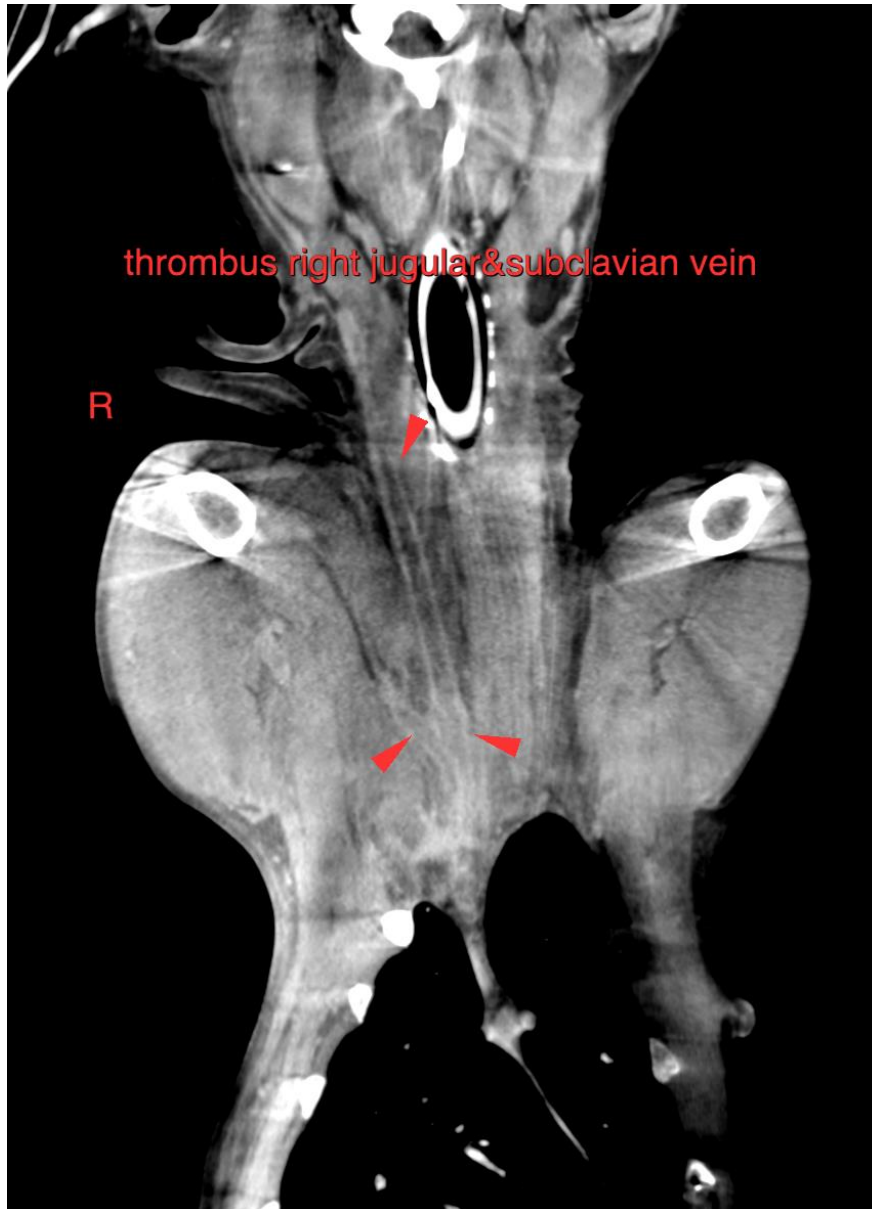
Dr. Young

INVOICE

53187

DATE

8-1-22





PATIENT

Jasmine Smith

SPECIES

Canine

BREED

Shepherd Mix

SEX

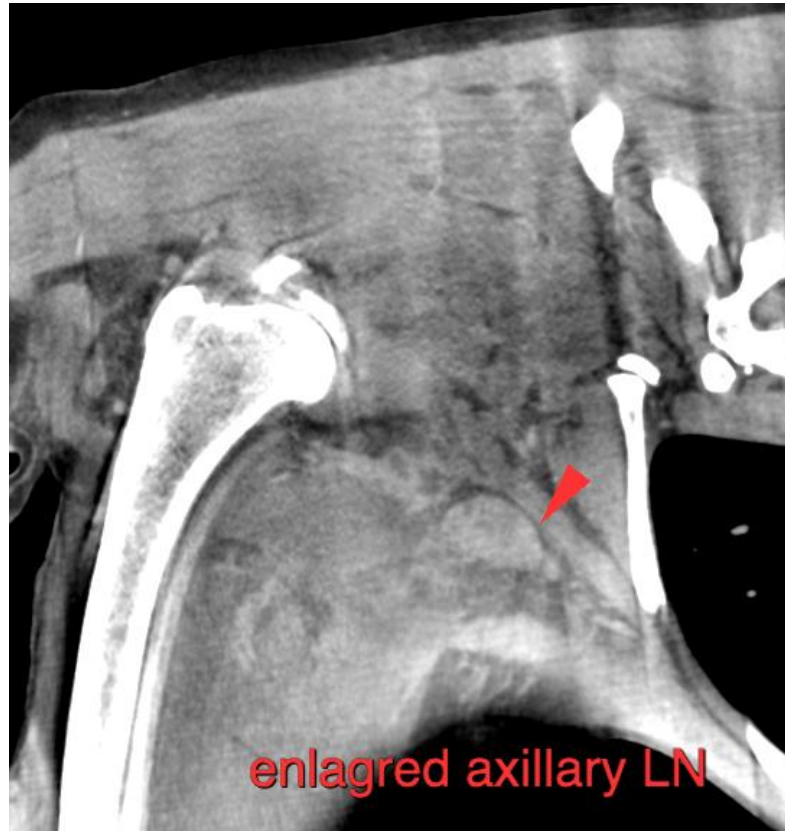FS

AGE

11 Years

INTERPRETED BY

Sebastian Schaub, DVM
Dr. med. vet. DipECVCI



HOSPITAL NAME

Critical Vet
Care/Suncoast
Veterinary

REFERRING VET

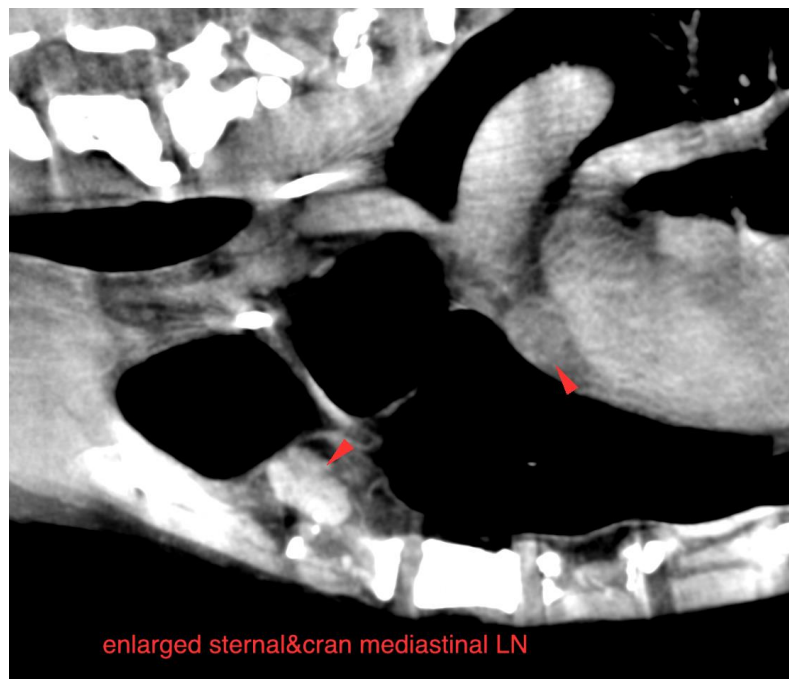Dr. Young

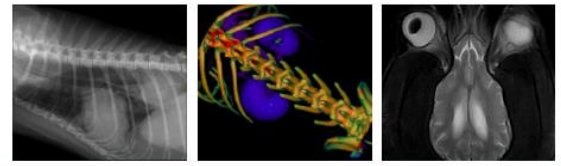
INVOICE

53187

DATE

8-1-22





PATIENT

Jasmine Smith

SPECIES

Canine

BREED

Shepherd Mix

SEX

FS

AGE

11 Years

INTERPRETED BY

Sebastian Schaub, DVM
Dr. med. vet. DipECVDI

HOSPITAL NAME

Critical Vet
Care/Suncoast
Veterinary

REFERRING VET

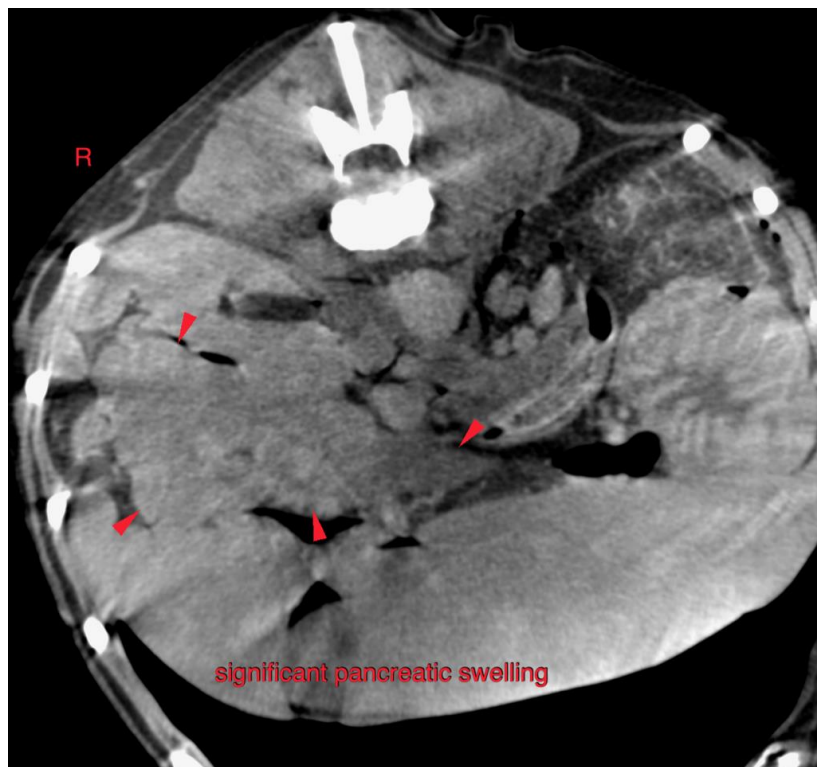
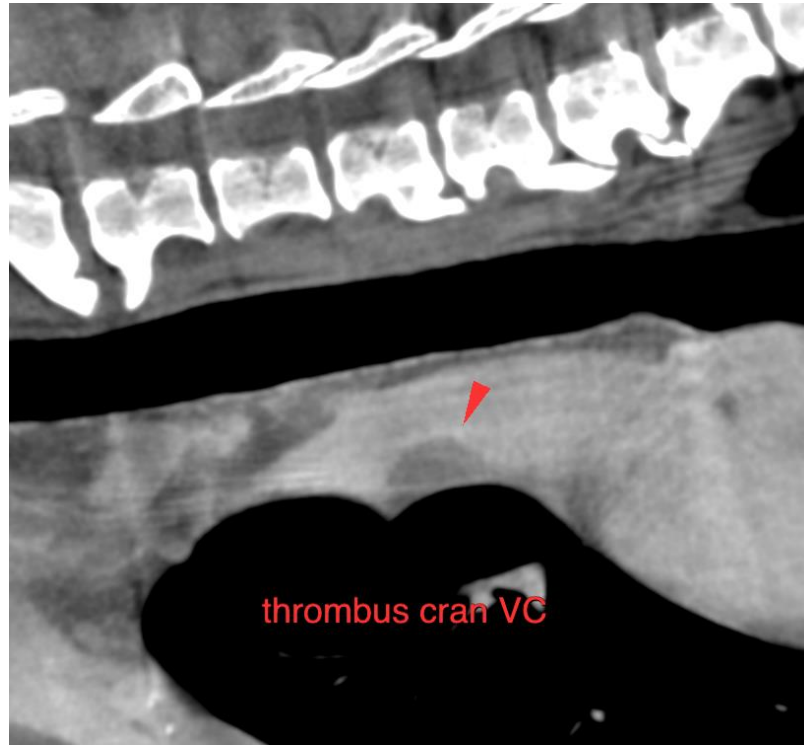
Dr. Young

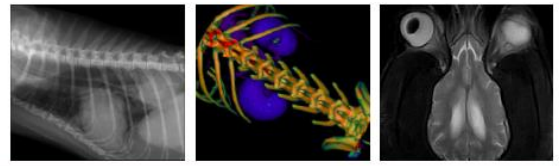
INVOICE

53187

DATE

8-1-22





PATIENT

Jasmine Smith

The information and recommendations provided are based on the images presented by the referring veterinarian/sonographer. No evaluation can be communicated regarding pathology that was not visible in the image/video clips provided.

SPECIES

Canine

Thank you for this referral. If the clinical or image interpretation does not parallel your findings or if I can be of any further assistance please contact me.

BREED

Shepherd Mix

Sebastian Schaub, Sebastian Schaub, DVM, Dr. med. vet. DipECVDI
sebast.schaub@gmail.com

SEX

FS

AGE

11 Years

INTERPRETED BY

Sebastian Schaub, DVM
Dr. med. vet. DipECVDI

HOSPITAL NAME

Critical Vet
Care/Suncoast
Veterinary

REFERRING VET

Dr. Young

INVOICE

53187

DATE

8-1-22