



PATIENT

Eloise Kraft

PRESENTING CLINICAL SIGNS

O think that the abdomen is distended

RADIOGRAPHIC STUDY OF THE THORAX AND ABDOMEN

SPECIES

Canine

A right lateral view of the thorax and abdomen is provided for review.

RADIOGRAPHIC FINDINGS

Thorax

BREED

Labrador Retriever

The surrounding bony structures are within normal limits.

The extrathoracic soft tissues present homogeneous without abnormalities.

The heart is of normal size and shape, there is no evidence of cardiac chamber or vascular enlargement. The pulmonary vasculature is within normal limits.

SEX

Female/sp

The trachea is normal in diameter and presents the anticipated course. The luminal outline of the trachea is smooth.

The bronchial tree presents with thin walls and tapers uniformly towards the periphery as expected.

AGE

8 Years

The lung parenchyma presents the expected architecture and opacity with randomly interspersed punctuate mineralization of the lung parenchyma; the intrapulmonary vascular branching is seen up to the third order lung vessels.

INTERPRETED BY

Sebastian Schaub, DVM
Dr. med. vet. DipECVDI

The diaphragm is well delineated with even surface and the expected mild cranial bulging of the diaphragmatic cupola.

Abdomen

HOSPITAL NAME

New Bridge
Veterinary Practice

The surrounding bony structures are within normal limits.

No abnormalities of the extraabdominal soft tissues are noted. The abdominal wall is smooth and thin.

The serosal detail is maintained throughout the peritoneal and retroperitoneal space.

REFERRING VET

Dr. Abina Glennon

The liver is appropriate in position, size and presents uniform opacity.

The splenic body and tail are considered normal for position, size, shape and opacity.

Both kidneys are seen and present with normal size, shape, delineation and opacity. The urinary bladder is in its anticipated position. No radiopaque calculi are noted throughout the upper and lower urinary tract.

INVOICE

53502

The stomach is in its anticipated position and presents normal content.

The small intestinal loops are of even diameter and non-dilated, a small amount of gas is seen within the small intestinal loops and considered within normal limits.

DATE

8-16-22

The colon is seen in the expected position and presents with appropriate content.



PATIENT

Eloise Kraft

RADIOGRAPHIC DIAGNOSIS

- Pulmonary osteomas, otherwise normal thorax
- Normal abdomen

SPECIES

Canine

INTERPRETATION OF THE FINDINGS & FURTHER RECOMMENDATIONS

The radiographic study of the thorax and the abdomen presents without clinically relevant pathology. There is no evidence of organomegaly/abdominal mass.

BREED

Labrador Retriever

SEX

Female/sp

AGE

8 Years

INTERPRETED BY

Sebastian Schaub, DVM
Dr. med. vet. DipECVDI

HOSPITAL NAME

New Bridge
Veterinary Practice

REFERRING VET

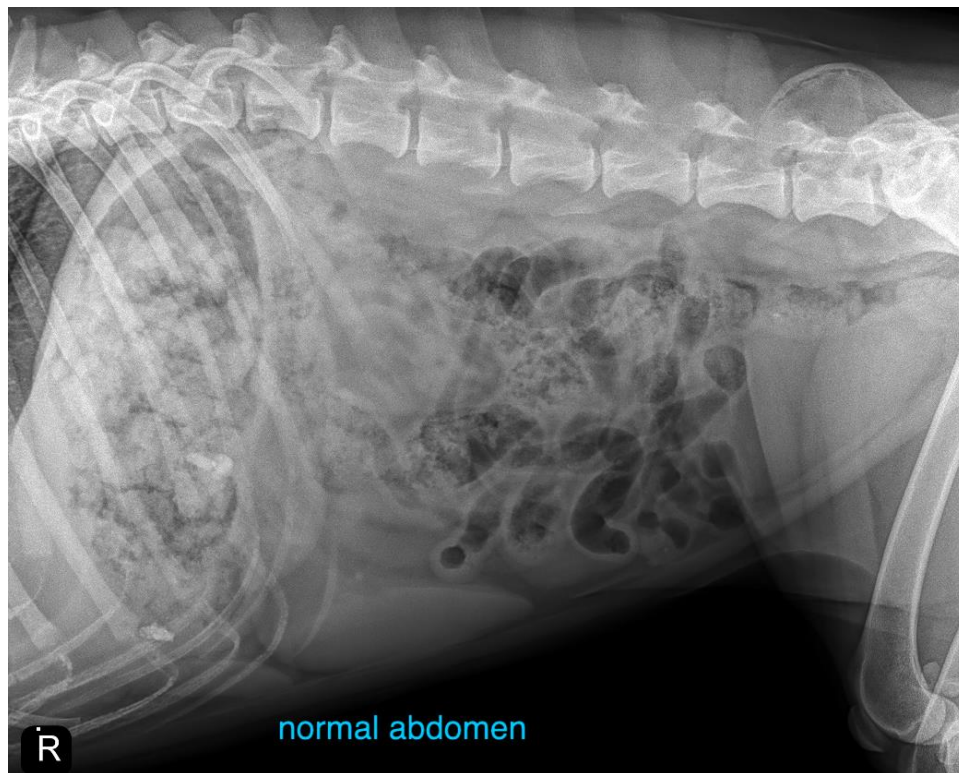
Dr. Abina Glennon

INVOICE

53502

DATE

8-16-22





PATIENT

Eloise Kraft

SPECIES

Canine

BREED

Labrador Retriever

SEX

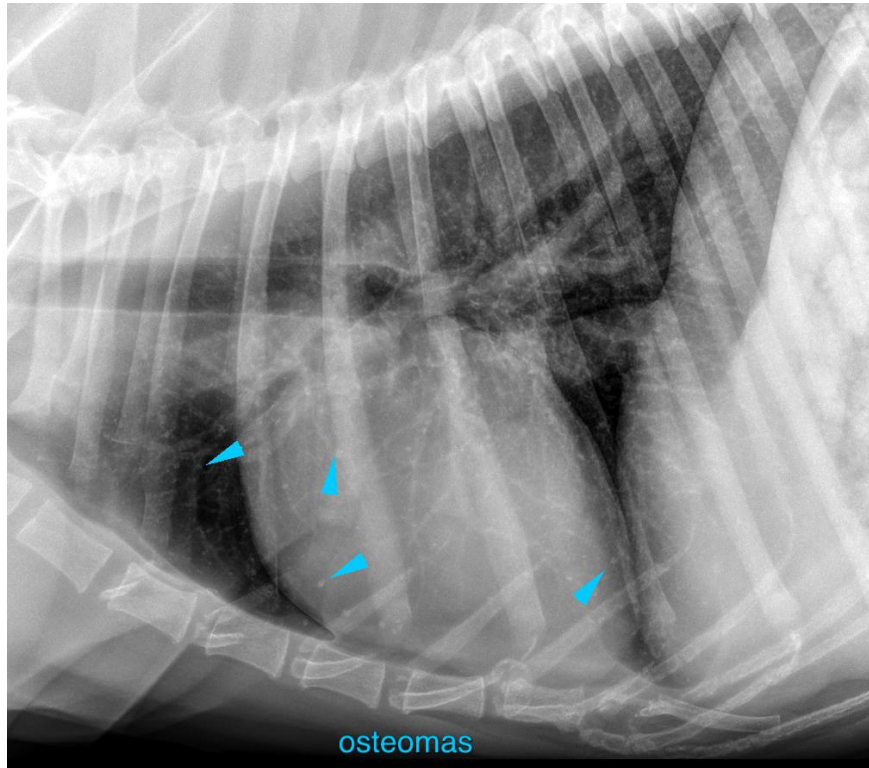
Female/sp

AGE

8 Years

INTERPRETED BY

Sebastian Schaub, DVM
Dr. med. vet. DipECVDI



HOSPITAL NAME

New Bridge
Veterinary Practice

REFERRING VET

Dr. Abina Glennon

INVOICE

53502

DATE

8-16-22

The information and recommendations provided are based on the images presented by the referring veterinarian/sonographer. No evaluation can be communicated regarding pathology that was not visible in the image/video clips provided.

Thank you for this referral. If the clinical or image interpretation does not parallel your findings or if I can be of any further assistance please contact me.

Sebastian Schaub, Sebastian Schaub, DVM, Dr. med. vet. DipECVDI
sebast.schaub@gmail.com