

**PATIENT PRESENTING CLINICAL SIGNS**

Lasie Gonzalez S: here for refill of all medications, including trazodone limping since last night, happened all of the sudden when owner was giving a bath and she ran nail trim + ear cleaning bump between legs, owner noticed one week ago and hasn't changed since then otherwise ok eats health extension wet food 1 can per day, has always eaten this food since a puppy per o O: fatty lump at the RH inguinal area dental calculus and gingivitis obese BCS 9/9 joint crepitus LH A: r/o lipoma dental ds r/o DJD r/o trauma r/o luxating patella r/o CCL rupture P: ear cleaning NT cbc/chem/T4/4Dx UA 2 view rads with consult RH

SPECIES

Canine

BREED

Mixed

RADIOGRAPHIC STUDY OF THE STIFLE JOINTS

Radiographs of the stifle joints are provided for review.

SEX

FS

RADIOGRAPHIC FINDINGS

The periarticular bones of both stifle joints present moderate osteophyte new bone formation. The left stifle joint presents mild intracapsular soft tissue swelling.

RADIOGRAPHIC DIAGNOSIS**AGE**

9

- Moderate degenerative osteoarthritis stifle joints bilaterally
- Mild articular swelling left stifle joint

INTERPRETED BYSebastian Schaub, DVM
Dr. med. vet. DipECVDI**INTERPRETATION OF THE FINDINGS & FURTHER RECOMMENDATIONS**

The radiographic study presents evidence of moderate degenerative joint disease of both stifle joints and mild joint effusion of the left stifle joint. The most common cause for degenerative joint disease of the stifle joints is pathology of the cranial cruciate ligament ± meniscal pathology.

HOSPITAL NAMEAnimal Paradise
Hospital**REFERRING VET**

Dr. Hellwarth

INVOICE

59374

DATE

7-8-23



PATIENT

Lasie Gonzalez

SPECIES

Canine

BREED

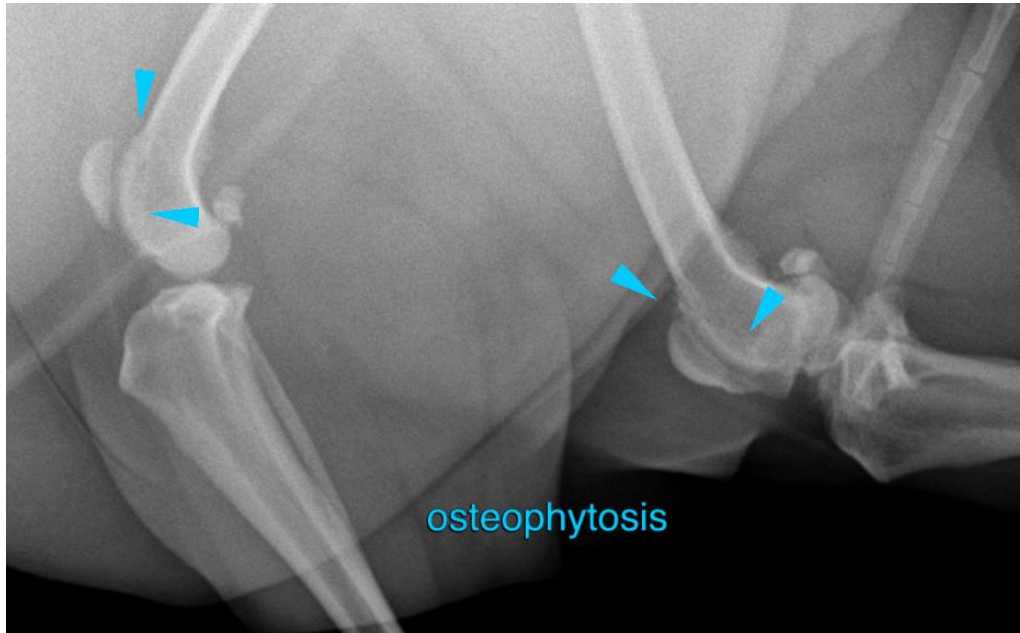
Mixed

SEX

FS

AGE

9



INTERPRETED BY

Sebastian Schaub, DVM
Dr. med. vet. DipECVDI

The information and recommendations provided are based on the images presented by the referring veterinarian/sonographer. No evaluation can be communicated regarding pathology that was not visible in the image/video clips provided.

Thank you for this referral. If the clinical or image interpretation does not parallel your findings or if I can be of any further assistance please contact me.

HOSPITAL NAME

Animal Paradise
Hospital

Sebastian Schaub, Sebastian Schaub, DVM, Dr. med. vet. DipECVDI
info@sonopath.com

REFERRING VET

Dr. Hellwarth

INVOICE

59374

DATE

7-8-23