



PATIENT PRESENTING CLINICAL SIGNS

Chance Ayars History: Epistaxis

COMPUTED TOMOGRAPHIC STUDY OF THE SKULL & THORAX

SPECIES

Canine A high resolution pre- and post-contrast CT study of the skull and a post-contrast CT study of the thorax are provided for review.

COMPUTED TOMOGRAPHIC FINDINGS

BREED

Husky **Skull**

Triadan 208 is absent, the respective alveolar bone presents with moth eaten osteolytic lesions with perforation of the cortex laterally.

SEX

Neutered Male The caudodorsal aspect of the left nasal cavity is occupied by a uniform soft tissue attenuating and moderate contrast enhancing mass. Destruction of the associated conchal & turbinate structure is appreciated.

AGE

14 Years Both temporomandibular joints present congruent joint spaces with even subchondral bone surfaces and are considered within normal limits.

Both tympanic bullae are aerated, the mucosal lining is not seen, the bony wall is smooth and thin. The external ear canals are within normal limits.

INTERPRETED BY

Sebastian Schaub, DVM
Dr. med. vet. DipECVDI

The brain presents no deviation from normal anatomy and symmetry. The brain parenchyma is homogeneous and within normal limits for attenuation and distribution of contrast enhancement. The ventricular system is non-dilated and symmetric.

HOSPITAL NAME

Mobile Pet Imaging

The submandibular and medial retropharyngeal lymph nodes are small and elongated with a normal short-to-long-axis-ratio is < 0.5, the attenuation and contrast enhancement pattern is uniform.

Thorax

REFERRING VET

Meaux

Multifocal mild spondylosis formation is present along the thoracic spine. In the right axillary region, an intermuscular lipoma is seen.

INVOICE

16551

In axis-ratio is < 0.5, the attenuation and contrast enhancement pattern is uniform and considered within normal limits.

The cardiovascular structures are within normal limits. Multifocal mild mineralization of the wall of the pulmonary arteries is visible.

DATE

7/8/22



PATIENT

Chance Ayars

The bronchial tree presents with regular branching and tapers uniformly towards the periphery as expected, the bronchial walls are thin and smooth. The bronchus-to-artery ratio is within normal limits.

The lung parenchyma presents the expected architecture and attenuation behavior.

SPECIES

Canine

Small incidental gas pockets are seen within the esophageal lumen, there is no evidence of abnormal dilation.

COMPUTED TOMOGRAPHIC DIAGNOSIS

BREED

Husky

- Left sided nasal soft tissue mass
- Multifocal mild dystrophic mineralization of the pulmonary arteries
- Absent triadan 208 with evidence of preceding tooth root infection
- No evidence of pulmonary metastatic disease

SEX

Neutered Male

INTERPRETATION OF THE FINDINGS & FURTHER RECOMMENDATIONS

The left sided nasal mass is suggestive for primary nasal neoplasia. Differentials include adenocarcinoma, squamous cell carcinoma, Sticker sarcoma, transitional cell carcinoma, lymphosarcoma, other. Theoretically granulomatous nasal disease is a potential (e.g. Leishmaniasis, mycotic), but the odds are considered low. Rhinoscopy including FNA sampling can be used as advanced diagnostic tests. Based on the results of the advanced diagnostic tests, the chances of radiation therapy can be discussed with oncologist. The Adam tumor stage is T1.

AGE

14 Years

INTERPRETED BY

Sebastian Schaub, DVM
Dr. med. vet. DipECVDI

The mineralization of the pulmonary arteries can be caused by a preceding or ongoing parasitic infection, such as *Angiostrongylus* or *Dirofilaria*. Testing for potential infection following the guidelines of the "American Heartworm Society" <https://www.heartwormsociety.org> is recommended.

HOSPITAL NAME

Mobile Pet Imaging

REFERRING VET

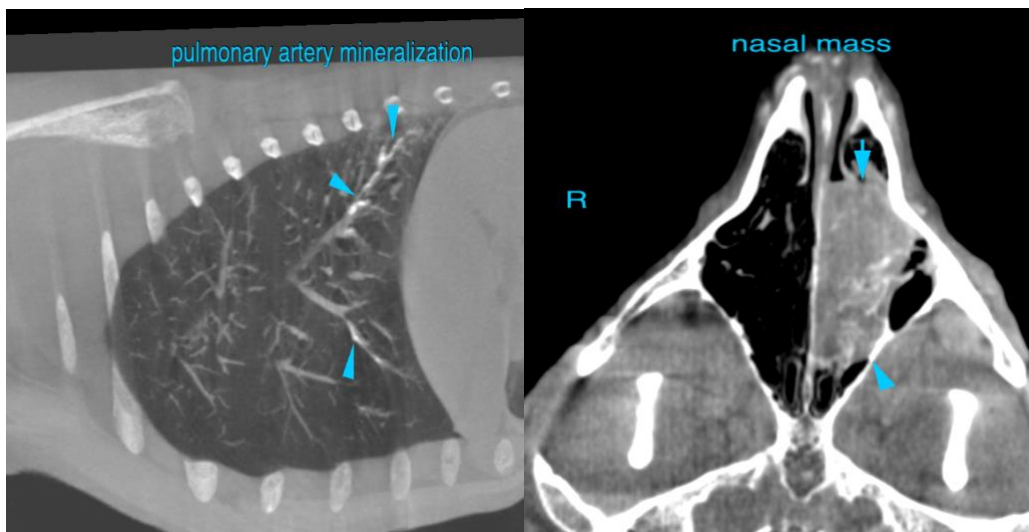
Meaux

INVOICE

16551

DATE

7/8/22





PATIENT

The information and recommendations provided are based on the images presented by the referring veterinarian/sonographer. No evaluation can be communicated regarding pathology that was not visible in the image/video clips provided.

Chance Ayars

SPECIES

Thank you for this referral. If the clinical or image interpretation does not parallel your findings or if I can be of any further assistance please contact me.

Canine

Sebastian Schaub, Sebastian Schaub, DVM, Dr. med. vet. DipECVDI
sebast.schaub@gmail.com

BREED

Husky

SEX

Neutered Male

AGE

14 Years

INTERPRETED BY

Sebastian Schaub, DVM
Dr. med. vet. DipECVDI

HOSPITAL NAME

Mobile Pet Imaging

REFERRING VET

Meaux

INVOICE

16551

DATE

7/8/22