



**PATIENT PRESENTING CLINICAL SIGNS**

Tazie Froggatt History: interdigital cyst between 3rd and 4th digit. Inflamed but no purulent discharge, uncomfortable at palpation

**SPECIES COMPUTED TOMOGRAPHIC STUDY OF THE LEFT HIND PAW**

Canine A high-resolution plain CT study of the left hind paw is provided for review.

**COMPUTED TOMOGRAPHIC FINDINGS**

**BREED**

Bull Dog An interdigital, homogeneous, soft tissue swelling is appreciated between the third and fourth phalanx.  
The osseous structures of the left hind paw present no abnormalities.

**SEX**

The pictured parts of the distal intertarsal joints present mild osteophyte new bone formation.

Female

**COMPUTED TOMOGRAPHIC DIAGNOSIS**

**AGE**

- History of interdigital cyst 3<sup>rd</sup> and 4<sup>th</sup> phalanx
- Mild degenerative osteoarthritis distal intertarsal joints

9 Years

**INTERPRETATION OF THE FINDINGS & FURTHER RECOMMENDATIONS**

The appreciated soft tissue swelling is fitting the history of an interdigital cyst, the associated osseous structures present no abnormalities. In case of strong clinical suspicion for migrating foreign material, recommend complementing workup by an ultrasound examination.

**INTERPRETED BY**

Sebastian Schaub,  
DVM Dr. med. vet.  
DipECVDI

**HOSPITAL NAME**

Animal Trust Bolton

**REFERRING VET**

Animal Trust

**INVOICE**

23237

**DATE**

7/7/23



**PATIENT**

Tazie Froggatt

**SPECIES**

Canine

**BREED**

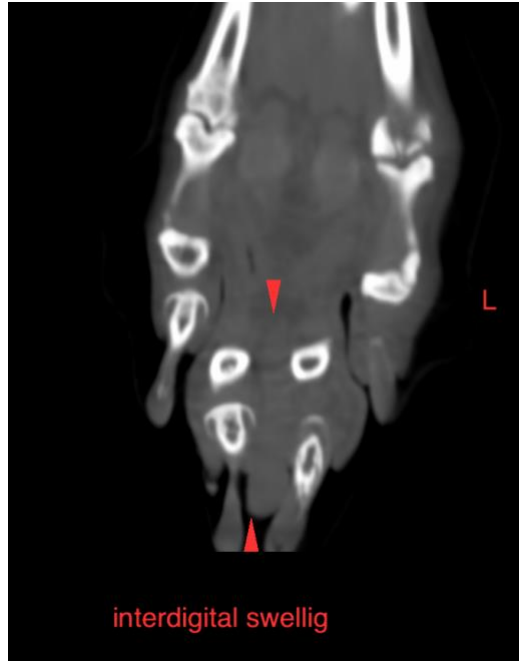
Bull Dog

**SEX**

Female

**AGE**

9 Years



**The information and recommendations provided are based on the images presented by the referring veterinarian/sonographer. No evaluation can be communicated regarding pathology that was not visible in the image/video clips provided.**

**INTERPRETED BY**

Sebastian Schaub,  
DVM Dr. med. vet.  
DipECVDI

Thank you for this referral. If the clinical or image interpretation does not parallel your findings or if I can be of any further assistance please contact me.

**HOSPITAL NAME**

Animal Trust Bolton

**Sebastian Schaub**, Sebastian Schaub, DVM, Dr. med. vet. DipECVDI  
info@sonopath.com

**REFERRING VET**

Animal Trust

**INVOICE**

23237

**DATE**

7/7/23