



**PATIENT PRESENTING CLINICAL SIGNS**

Mufasa Fineman History: Lipoma on Ventral Neck partially overlapping trachea toward Right side causing coughing- This CT is for surgical Planning with a Met check. R/O involvement of vessels/nerves with the lipoma

**SPECIES COMPUTED TOMOGRAPHIC STUDY OF THE NECK & THORAX**

Canine A high resolution pre- and post-contrast CT study of the neck and a post-contrast CT study of the thorax are provided for review.

**BREED COMPUTED TOMOGRAPHIC FINDINGS**

Pitbull **Neck**

**SEX** In the subcutaneous tissue at the right caudoventral aspect of the larynx, a uniform fat-attenuating lesion, measuring 4.9 x 1.4 x 5.2 cm. The fat-attenuating lesion is demarcated by a thin, soft tissue capsule.

Neutered Male

Multifocal mild spondylosis formation is seen along the cervical spine.

**AGE** The remainder of the osseous and soft tissue structures along the neck are appreciated.

10 Years

**Thorax**

**INTERPRETED BY**

Multifocal moderate spondylosis formation is seen along the thoracic spine.

Sebastian Schaub,  
DVM Dr. med. vet.  
DipECVDI

Parts of the thorax are cropped by the field of view.

The mediastinal and tracheobronchial lymph nodes are small elongated with a normal short-to-long-axis-ratio is < 0.5, the attenuation and contrast enhancement pattern is uniform and considered within normal limits.

**HOSPITAL NAME**

Advanced Animal  
Imaging

The cardiovascular structures including the pulmonary vasculature are within normal limits.

**REFERRING VET**

Dr. Blair Hollowell

The bronchial tree presents with regular branching and tapers uniformly towards the periphery as expected, the bronchial walls are thin and smooth. The bronchus-to-artery ratio is within normal limits.

The caudodorsal dependent aspects of the lung parenchyma present zones with dystelectasis. The remainder of the lung parenchyma present the expected architecture and attenuation behavior with randomly distributed interspersed punctuate mineralization.

**INVOICE**

23238

Small incidental gas pockets are seen within the esophageal lumen, there is no evidence of abnormal dilation.

**COMPUTED TOMOGRAPHIC DIAGNOSIS**

**DATE**

7/7/23



**PATIENT**

Mufasa Fineman

- Lipoma caudoventral aspect of the larynx
- Pulmonary osteomas
- Spondylosis deformans
- No evidence of pulmonary metastatic disease

**SPECIES**

Canine

**INTERPRETATION OF THE FINDINGS & FURTHER RECOMMENDATIONS**

The lipoma at the caudoventral aspect of the larynx is well-defined and there is no evidence of involvement of anatomical delicate structures – complete surgical excision is feasible.

**BREED**

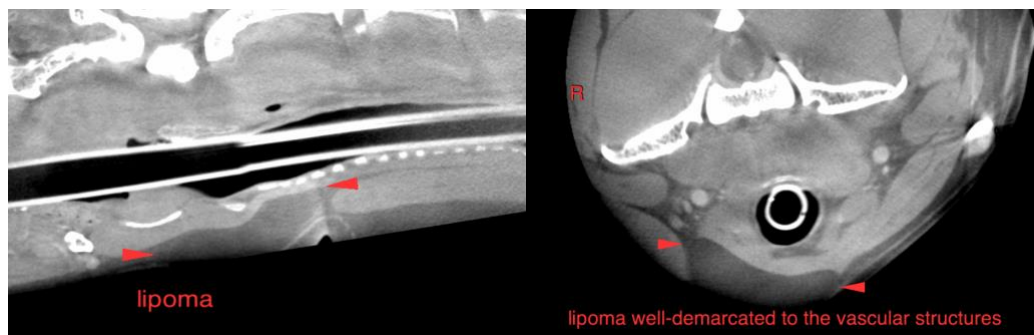
Pitbull

**SEX**

Neutered Male

**AGE**

10 Years



**The information and recommendations provided are based on the images presented by the referring veterinarian/sonographer. No evaluation can be communicated regarding pathology that was not visible in the image/video clips provided.**

**INTERPRETED BY**

Sebastian Schaub,  
DVM Dr. med. vet.  
DipECVDI

Thank you for this referral. If the clinical or image interpretation does not parallel your findings or if I can be of any further assistance please contact me.

**Sebastian Schaub**, Sebastian Schaub, DVM, Dr. med. vet. DipECVDI  
info@sonopath.com

**HOSPITAL NAME**

Advanced Animal  
Imaging

**REFERRING VET**

Dr. Blair Hollowell

**INVOICE**

23238

**DATE**

7/7/23