



PATIENT PRESENTING CLINICAL SIGNS

Rupert Collins History: Resolving cervical pain and chronic pruritus/scratching at the left face/ear (months). Previous cervical pain 1 year ago. Investigation to rule out congenital malformation or IVDH.

SPECIES MAGNETIC RESONANCE IMAGING OF THE CERVICAL SPINE

Canine All intervertebral discs along the cervical spine present a moderate to complete loss of the in fluid sensitive sequences hyperintense signal of the nucleus pulposus.

BREED The intervertebral discs C2/C3 and C6/C7 are mildly bulging into the vertebral canal, distorting the ventral epidural space at the same level.

French Bulldog

Post contrast administration, no pathological contrast enhancement pattern is seen along the cervical spine.

SEX

Neutered Male

Both tympanic bullae are filled with T2 hyperintense material.

MAGNETIC RESONANCE IMAGING DIAGNOSIS

AGE

3 Years

- Mild to moderate intervertebral disc protrusion C2/C3 and C6/C7 with potential dynamic compressive myelopathy
- Generalized degenerative disc disease along the cervical spine
- Bilateral otitis media – suspect primary secretory

INTERPRETED BY

Sebastian Schaub,
DVM Dr. med. vet.
DipECVDI

INTERPRETATION OF THE FINDINGS & FURTHER RECOMMENDATIONS

The mild intervertebral disc protrusion C2/C3 and C6/C7 can be a source for intermittent cervical pain – especially level C2/C3.

HOSPITAL NAME

Animal Health
Partners

No congenital abnormalities along the cervical spine are appreciated.

REFERRING VET

Dr. Edouard Marchal

INVOICE

16524

DATE

7/7/22



PATIENT

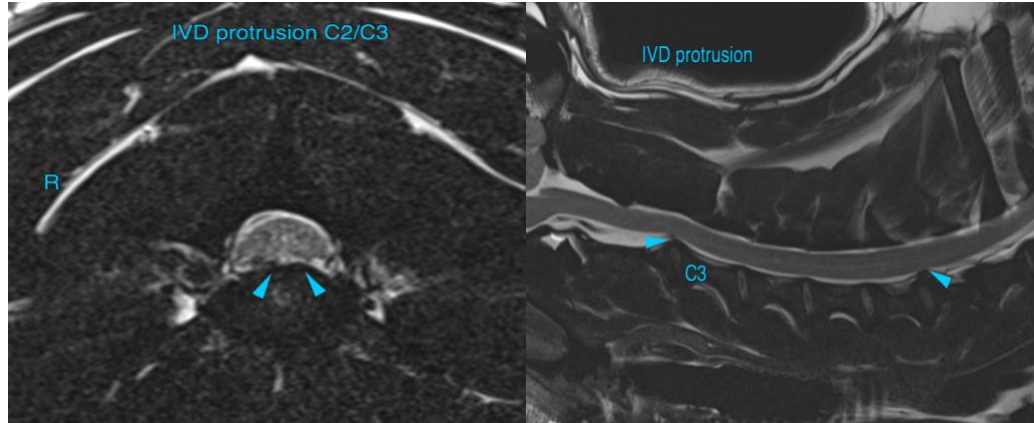
Rupert Collins

SPECIES

Canine

BREED

French Bulldog



SEX

Neutered Male

AGE

3 Years

The information and recommendations provided are based on the images presented by the referring veterinarian/sonographer. No evaluation can be communicated regarding pathology that was not visible in the image/video clips provided.

Thank you for this referral. If the clinical or image interpretation does not parallel your findings or if I can be of any further assistance please contact me.

Sebastian Schaub, Sebastian Schaub, DVM, Dr. med. vet. DipECVDI
sebast.schaub@gmail.com

INTERPRETED BY

Sebastian Schaub,
DVM Dr. med. vet.
DipECVDI

HOSPITAL NAME

Animal Health
Partners

REFERRING VET

Dr. Edouard Marchal

INVOICE

16524

DATE

7/7/22