



PATIENT

Chelsea Geada

PRESENTING CLINICAL SIGNS

P had one seizure 2 Fridays ago and then two days ago had 4 and another last night while hospitalized. kicking, clenched mouth, foaming for approx 2 minutes each and dazed afterwards for 2-3 minutes; hx of ai disease; had blood transfusion approx 5-6 years ago suppressed proprioceptive, neuro reflexes; anorexic w/hx of oa/djd

SPECIES

Canine

COMPUTED TOMOGRAPHY OF THE SKULL AND ENTIRE SPINE

A plain & post contrast CT study of the cervical, thoracic and lumbar spine and is provided for review.

BREED

German Shepard

COMPUTED TOMOGRAPHIC FINDINGS

Skull

The pictured parts of the dentition are complete and unremarkable in all jaw quadrants. Multifocal punctuate mineralization of the tongue is visible.

SEX

Female Spayed

Mild striated mineralization of the temporal musculature bilaterally is seen.

AGE

13 Years

Both temporomandibular joints present congruent joint spaces with even subchondral bone surfaces and are considered within normal limits.

The left tympanic bulla is filled with uniform soft tissue attenuating material, the osseous lining is smooth and thin. The external ear canals present a mild irregular epithelial lining.

INTERPRETED BY

Sebastian Schaub, DVM
Dr. med. vet. DipECVDI

In left supratentorial region, level with the left occipital lobe, a mild hyperattenuating irregular convex shaped mass is visible, presenting a broad contact to the tentorium osseum cerebelli; measuring 11 x 8 x 11 mm in size.

The submandibular and medial retropharyngeal lymph nodes are small and elongated with a normal short-to-long-axis-ratio is < 0.5, the attenuation and contrast enhancement pattern is uniform.

HOSPITAL NAME

Westwood Regional
Veterinary Hospital

Spine

The intervertebral discs T4/T5 to T7/T8 and T12/T13 and T13/L1 are moderately protruding into the vertebral canal, occupying approximately up to 30% of the cross-sectional area of the vertebral canal at the same level. The dural tube is deviated dorsally respectively and mildly distorted.

REFERRING VET

Goldman

The remainder of the intervertebral discs of the thoracic and lumbar spine are mildly protruding into the vertebral canal, distorting the ventral epidural space and occupying approximately up to 15% of the cross-sectional area of the vertebral canal at the same level.

INVOICE

52758

Multifocal moderate spondylosis formation is seen along the thoracic & lumbar spine.

At the base of the heart, between the aortic arch and the trachea, a roundish, heterogeneous soft tissue attenuating mass, measuring 4.2 x 3.3 x 4.5 cm in size. The trachea at the same level is mildly deviated to the right.

DATE

7-7-22

Originating from the right adrenal gland, a roundish, heterogeneous soft tissue attenuating and contrast enhancing mass, measuring 4.5 x 3.9 x 5.5 cm in size. In the periphery of the right adrenal mass, fluid attenuating regions are visible. The caudal vena cava level with the right adrenal mass



PATIENT is deviated to the left and ventrally and is distorted.

Chelsea Geada Nodular enlargement of the cranial pole of the left adrenal gland is visible, measuring 13 mm in diameter.

SPECIES **COMPUTED TOMOGRAPHIC DIAGNOSIS**

Canine

- Intracranial supratentorial mild hyperattenuating likely extraaxial mass
- Right adrenal soft tissue mass with evidence of localized retroperitoneal hemorrhage
- Heart base mass
- Moderate intervertebral disc protrusion T4/T5 to T7/T8 and T12/T13 and T13/L1 with compressive myelopathy
- Multifocal mild intervertebral disc protrusion along the thoracic and lumbar spine without compressive myelopathy
- Suspect mild metastatic mineralization temporal musculature and tongue – possible hyperadrenocorticism
- Spondylosis deformans

BREED

German Shepard

SEX

Female Spayed

AGE

13 Years

INTERPRETED BY

Sebastian Schaub, DVM
Dr. med. vet. DipECVDI

HOSPITAL NAME

Westwood Regional
Veterinary Hospital

REFERRING VET

Goldman

INVOICE

52758

DATE

7-7-22

INTERPRETATION OF THE FINDINGS & FURTHER RECOMMENDATIONS

The intracranial supratentorial mass is highly suggestive for primary extraaxial neoplasia and meningioma is the top differential. The intracranial mass is a plausible explanation for the seizure activity.

There is a right adrenal mass, consistent with primary (non)functional adrenal neoplasia and adenocarcinoma or pheochromocytoma are likely here. The fluid attenuating material in the periphery of the right adrenal mass is highly concerning for hemorrhage originating from the mass. I do not see evidence of vascular invasion, but the contrast enhancement of the caudal vena cava is limited, and invasion cannot be ruled out entirely. Due to evidence of hemorrhage, surgical management would be the therapy of choice.

The heart base mass is most consistent with a third entity and paraganglioma is the presumptive diagnosis – commonly slow growing tumor that can predispose for pericardial effusion.

Nodular enlargement of the left adrenal gland can indicate macronodular hyperplasia or neoplastic disease (e.g. adenoma, adenocarcinoma, pheochromocytoma).



PATIENT

Chelsea Geada

SPECIES

Canine

BREED

German Shepard

SEX

Female Spayed

AGE

13 Years

INTERPRETED BY

Sebastian Schaub, DVM
Dr. med. vet. DipECVDI

HOSPITAL NAME

Westwood Regional
Veterinary Hospital

REFERRING VET

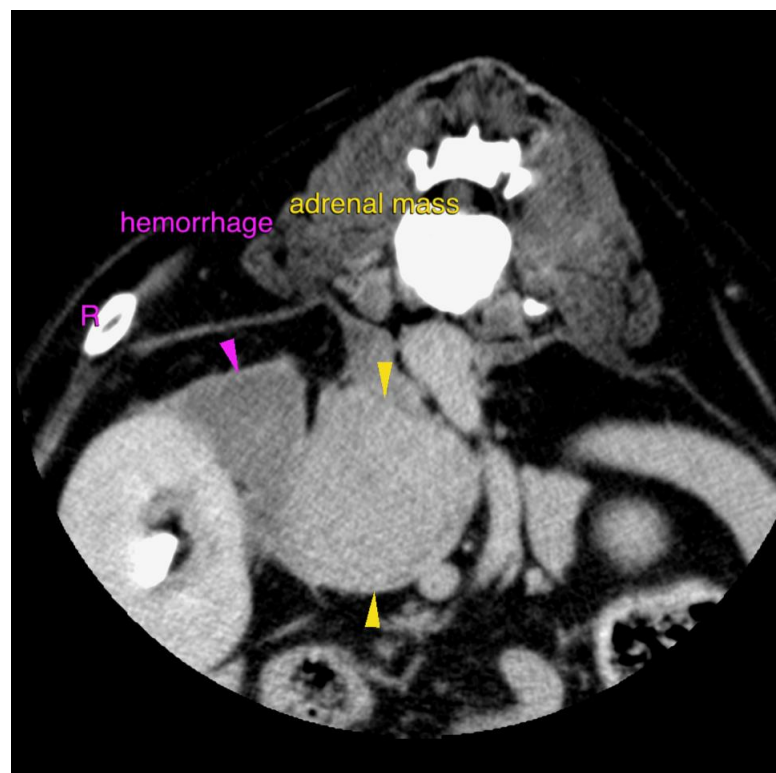
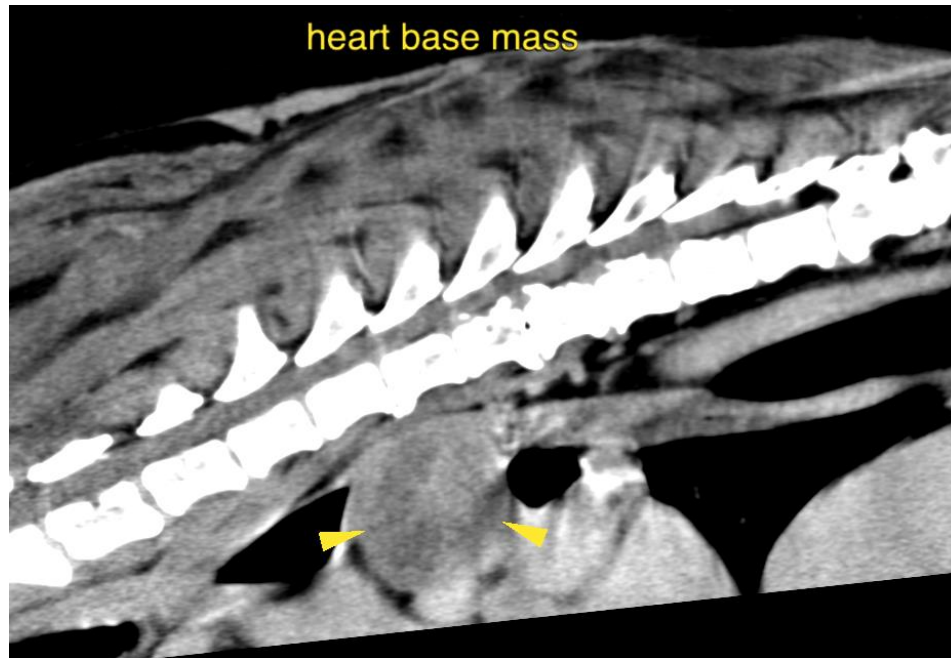
Goldman

INVOICE

52758

DATE

7-7-22





PATIENT

Chelsea Geada

SPECIES

Canine

BREED

German Shepard

SEX

Female Spayed

AGE

13 Years

INTERPRETED BY

Sebastian Schaub, DVM
Dr. med. vet. DipECVDI

HOSPITAL NAME

Westwood Regional
Veterinary Hospital

REFERRING VET

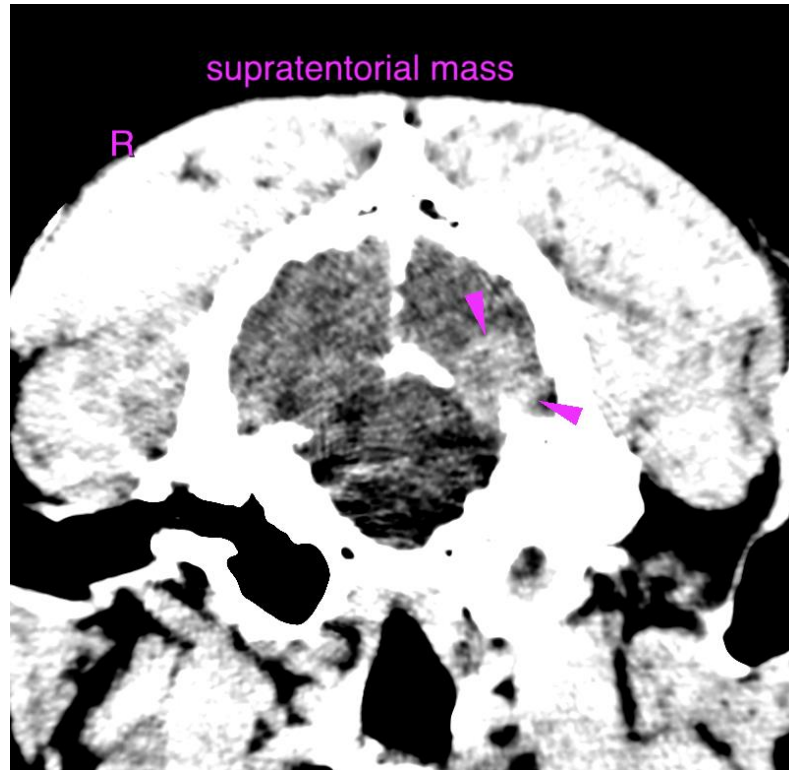
Goldman

INVOICE

52758

DATE

7-7-22



The information and recommendations provided are based on the images presented by the referring veterinarian/sonographer. No evaluation can be communicated regarding pathology that was not visible in the image/video clips provided.

Thank you for this referral. If the clinical or image interpretation does not parallel your findings or if I can be of any further assistance please contact me.

Sebastian Schaub, Sebastian Schaub, DVM, Dr. med. vet. DipECVDI
sebast.schaub@gmail.com