



PATIENT PRESENTING CLINICAL SIGNS

Precious Antunes last heat march/april 2023 drinking and urinating very little PE: nosf Blood work UA pending

RADIOGRAPHIC STUDY OF THE ABDOMEN

SPECIES Radiographs of the abdomen are provided for review.

Canine **RADIOGRAPHIC FINDINGS**

The surrounding bony structures are within normal limits.

BREED No abnormalities of the extraabdominal soft tissues are noted. The abdominal wall is smooth and thin.

Poodle Mix The serosal detail is maintained throughout the peritoneal and retroperitoneal space.

The liver is appropriate in position, size and presents uniform opacity.

SEX The splenic head is in the anticipated position and within normal limits for size and opacity. The splenic body and tail are considered normal for position, size, shape and opacity.

Female

Both kidneys are seen and present with normal size, shape, delineation and opacity. The urinary bladder is in its anticipated position. No radiopaque calculi are noted throughout the upper and lower urinary tract.

AGE

5.5 Years In the lateral projection of the abdomen, a Y-shaped tubular soft tissue opacity is superimposed on the urinary bladder, the diameter is equals the diameter of the small intestinal loops.

INTERPRETED BY

The stomach is in its anticipated position and presents normal content.

Sebastian Schaub, DVM
Dr. med. vet. DipECVDI

The small intestinal loops are of even diameter and non-dilated, a small amount of gas is seen within the small intestinal loops and considered within normal limits.

HOSPITAL NAME

The colon is seen in the expected position and presents with appropriate content.

The Pet Hospital of
Stratford

RADIOGRAPHIC DIAGNOSIS

- Mild prominent uterus

REFERRING VET

INTERPRETATION OF THE FINDINGS & FURTHER RECOMMENDATIONS

Dr. Robert Bashkin

The Y-shaped soft tissue opacity is consistent with a mild prominent uterus – can be normal finding depending on the stage of the heat cycle or indicate mild fluid filling (e.g. hydro-, muco-, hemo-, pyometra). Early stage of pregnancy would be a consideration as well. Ultrasound can be used for further workup.

INVOICE

59214

DATE

7-6-23



PATIENT

Precious Antunes

SPECIES

Canine

BREED

Poodle Mix

SEX

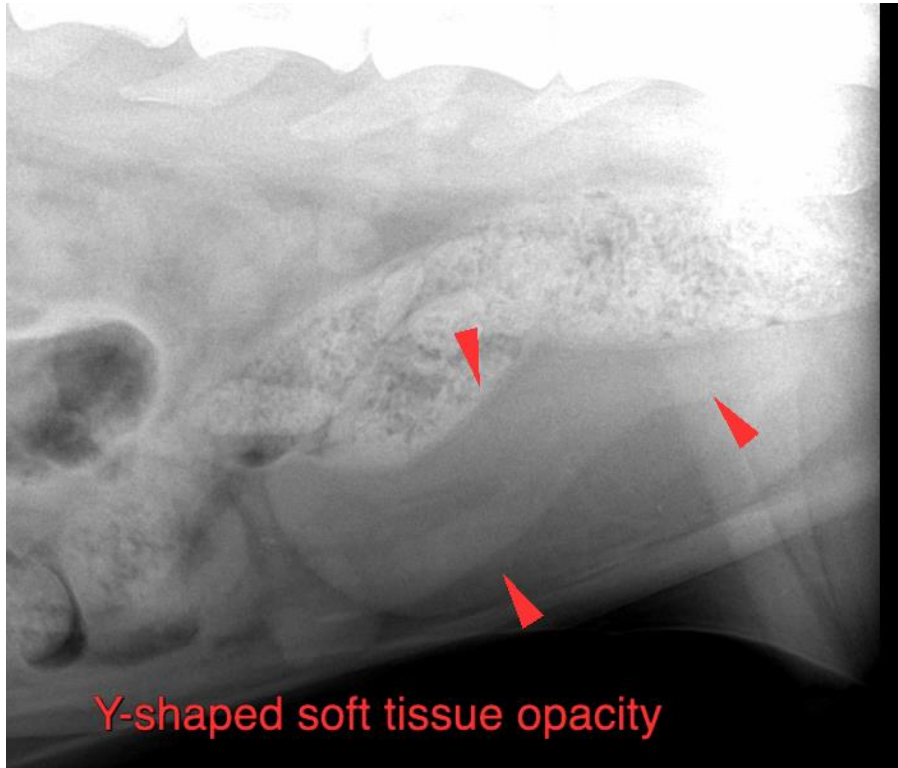
Female

AGE

5.5 Years

INTERPRETED BY

Sebastian Schaub, DVM
Dr. med. vet. DipECVDI



HOSPITAL NAME

The Pet Hospital of
Stratford

The information and recommendations provided are based on the images presented by the referring veterinarian/sonographer. No evaluation can be communicated regarding pathology that was not visible in the image/video clips provided.

Thank you for this referral. If the clinical or image interpretation does not parallel your findings or if I can be of any further assistance please contact me.

REFERRING VET

Dr. Robert Bashkin

Sebastian Schaub, Sebastian Schaub, DVM, Dr. med. vet. DipECVDI
info@sonopath.com

INVOICE

59214

DATE

7-6-23