



PATIENT PRESENTING CLINICAL SIGNS

Stitch Amram
 1 week history of P sporadically yelping. Has been panting more and harder time getting comfortable. Will unweight L forelimb.
 Abnormal PE/Chem/CBC/UA Results: Pain on cervical spine manipulation in all directions, but significantly on ventral motion.

SPECIES

Canine

RADIOGRAPHIC STUDY OF THE NECK

Radiographs of the neck in orthogonal imaging planes are provided for review.

BREED

Maltipoo

RADIOGRAPHIC FINDINGS

The intervertebral disc space C3/C4 is moderately narrowed, and mineralized material is seen in the imaging plane of the respective intervertebral disc space. Superimposed on the neuroforamen C3/C4, mineralized convex shaped material is appreciated.

SEX

MN

RADIOGRAPHIC DIAGNOSIS

- Discopathy C3/C4 with chondroid disc degeneration and potential intervertebral disc protrusion

AGE

7 Years

INTERPRETATION OF THE FINDINGS & FURTHER RECOMMENDATIONS

The radiographic changes are highly suggestive for protrusion of mineralized disc material level C3/C4, being a potential source for the presenting clinical signs. Cross-sectional imaging can be used to confirm the diagnosis and decision making if surgical decompression is beneficial.

INTERPRETED BY

Sebastian Schaub, DVM
 Dr. med. vet. DipECVDI

HOSPITAL NAME

Boca Park Animal Hospital

REFERRING VET

Hill

INVOICE

52733

DATE

7-6-22



PATIENT

Stitch Amram

SPECIES

Canine

BREED

Maltipoo

SEX

MN

AGE

7 Years

INTERPRETED BY

Sebastian Schaub, DVM
Dr. med. vet. DipECVDI

HOSPITAL NAME

Boca Park Animal
Hospital

REFERRING VET

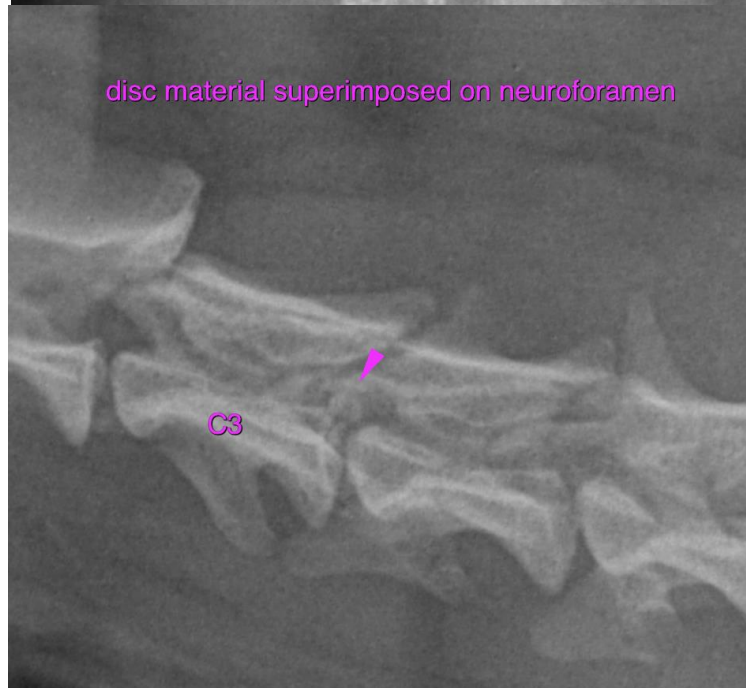
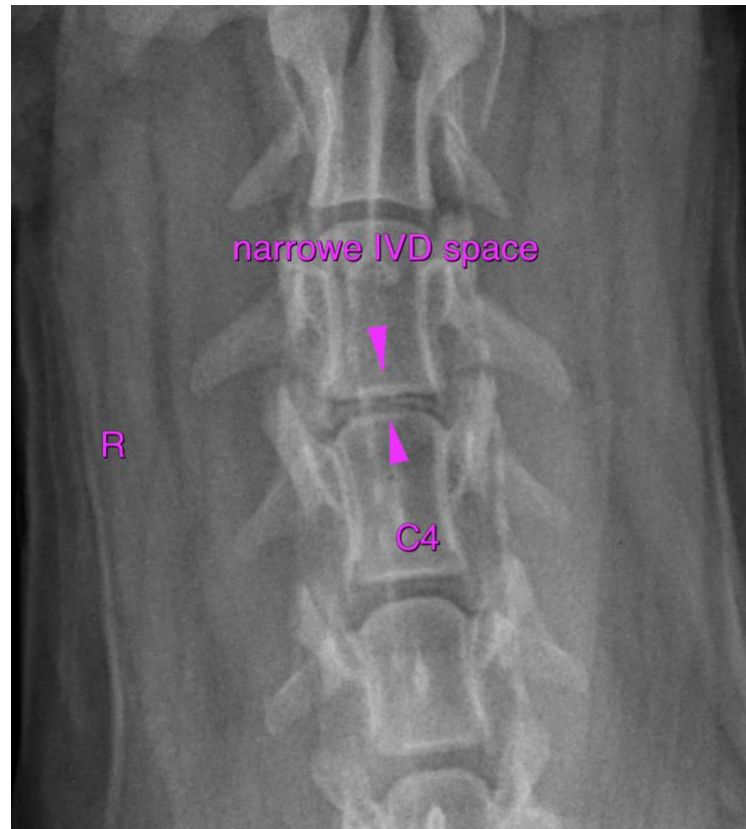Hill

INVOICE

52733

DATE

7-6-22





PATIENT

Stitch Amram

The information and recommendations provided are based on the images presented by the referring veterinarian/sonographer. No evaluation can be communicated regarding pathology that was not visible in the image/video clips provided.

Thank you for this referral. If the clinical or image interpretation does not parallel your findings or if I can be of any further assistance please contact me.

SPECIES

Canine

Sebastian Schaub, Sebastian Schaub, DVM, Dr. med. vet. DipECVDI
sebast.schaub@gmail.com

BREED

Maltipoo

SEX

MN

AGE

7 Years

INTERPRETED BY

Sebastian Schaub, DVM
Dr. med. vet. DipECVDI

HOSPITAL NAME

Boca Park Animal
Hospital

REFERRING VET

Hill

INVOICE

52733

DATE

7-6-22