



PATIENT

Rocco Osorio

PRESENTING CLINICAL SIGNS

Chronic severe weight bearing lameness on front Left leg -walking with elbow mostly flexed pain on elbow extension definitely the doctor can see arthritic changes

SPECIES

Canine

RADIOGRAPHIC STUDY OF THE SHOULDER AND ELBOW JOINTS

A complete set of radiographs of the shoulder and elbow joints is provided for review. Radiographs are dated 4/4/22.

BREED

English Bulldog

RADIOGRAPHIC FINDINGS

Mild osteophyte new bone formation is appreciated at the caudal aspect of the humeral head bilaterally.

Along the cranial aspect of the left humeral diaphysis, thin lamellar periosteal new bone formation is visible.

SEX

MN

Both elbow joints present moderate osteophyte new bone formation. The contour of the medial coronoid process bilaterally is ill-defined. At the base of the medial coronoid process of the left elbow joint, mild to moderate sclerosis is appreciated.

AGE

10 Years

RADIOGRAPHIC DIAGNOSIS

- Degenerative osteoarthritis elbow joints bilaterally, L>R
- Suspect coronoid disease elbow joints bilaterally
- Mild degenerative osteoarthritis elbow joints bilaterally, R>L

INTERPRETED BY

Sebastian Schaub, DVM
Dr. med. vet. DipECVDI

INTERPRETATION OF THE FINDINGS & FURTHER RECOMMENDATIONS

The degenerative joint disease of both elbow joints is likely a sequela to elbow dysplasia (e.g. FCP). The finding is a plausible source for the presenting clinical signs. If it is therapeutical relevant, workup can be complemented by a CT study of the elbow joints.

HOSPITAL NAME

Chappelle Veterinary
Clinic

The mild lamellar periosteal new bone formation at the cranial aspect of the left humeral diaphysis is very likely a benign finding, presenting the enthesis of the pectoral muscle.

REFERRING VET

Bassam Abdelmelak

INVOICE

52713

DATE

7-6-22



PATIENT

Rocco Osorio

SPECIES

Canine

BREED

English Bulldog

SEX

MN

AGE

10 Years

INTERPRETED BY

Sebastian Schaub, DVM
Dr. med. vet. DipECVDI

HOSPITAL NAME

Chappelle Veterinary
Clinic

REFERRING VET

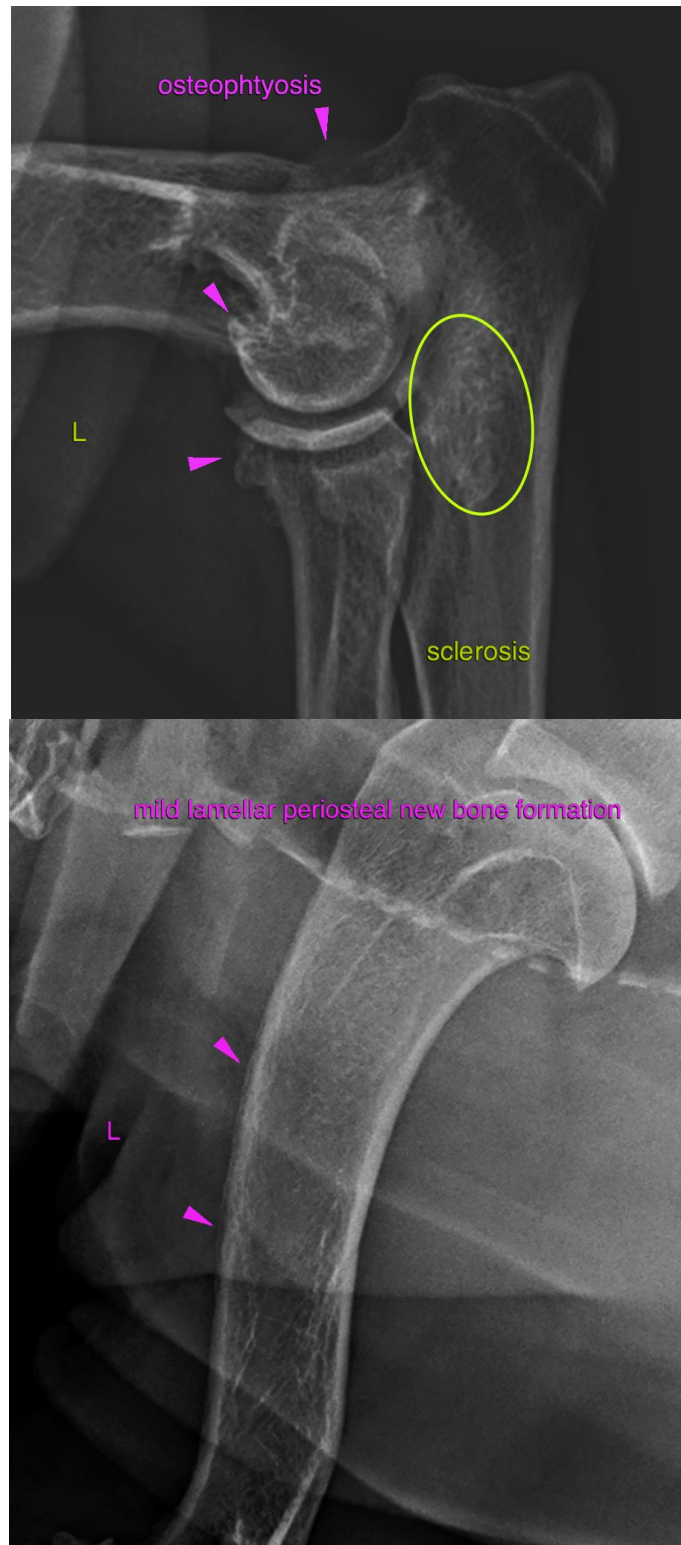
Bassam Abdelmelak

INVOICE

52713

DATE

7-6-22





PATIENT

Rocco Osorio

SPECIES

Canine

BREED

English Bulldog

SEX

MN

AGE

10 Years

INTERPRETED BY

Sebastian Schaub, DVM
Dr. med. vet. DipECVDI

HOSPITAL NAME

Chappelle Veterinary
Clinic

REFERRING VET

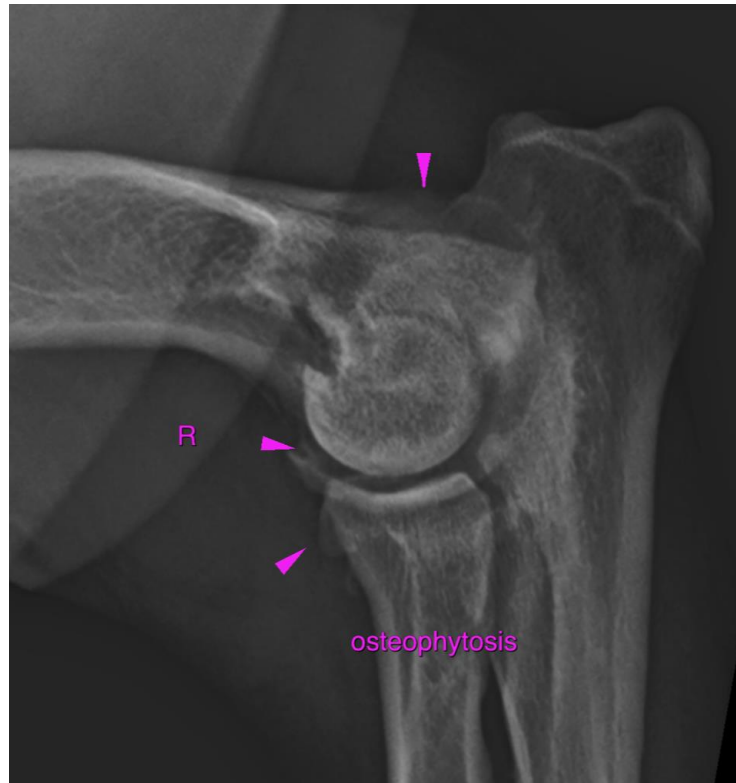
Bassam Abdelmelak

INVOICE

52713

DATE

7-6-22



The information and recommendations provided are based on the images presented by the referring veterinarian/sonographer. No evaluation can be communicated regarding pathology that was not visible in the image/video clips provided.

Thank you for this referral. If the clinical or image interpretation does not parallel your findings or if I can be of any further assistance please contact me.

Sebastian Schaub, Sebastian Schaub, DVM, Dr. med. vet. DipECVDI
sebast.schaub@gmail.com