

**PATIENT PRESENTING CLINICAL SIGNS**

Mister Smeltzer Sneezing for several months.

COMPUTED TOMOGRAPHY OF THE SKULL

SPECIES A high resolution pre- and post-contrast CT study of the skull is provided for review.

Feline **COMPUTED TOMOGRAPHIC FINDINGS**

The pictured parts of the dentition are complete and unremarkable in all jaw quadrants.

BREED In both nasal cavities, a moderate amount of non-contrast enhancing soft tissue material is attached to the nasal mucosal lining. Mild destruction of the nasal conchal structures is appreciated. The right frontal sinus is misshapen, presenting a significant prominent osseous lining.

SEX The left tympanic bulla is filled with non-contrast enhancing soft tissue material, forming a horizontal gas-fluid interface. The osseous lining of the left tympanic bulla is thin and smooth.

SEX MN Both temporomandibular joints present congruent joint spaces with even subchondral bone surfaces and are considered within normal limits.

The external ear canals are within normal limits.

AGE 8 Years The brain presents no deviation from normal anatomy and symmetry. The brain parenchyma is homogeneous and within normal limits for attenuation and distribution of contrast enhancement. The ventricular system is non-dilated and symmetric.

INTERPRETED BY

Sebastian Schaub, DVM
Dr. med. vet. DipECVDI

The submandibular and medial retropharyngeal lymph nodes are small and elongated with a normal short-to-long-axis-ratio is < 0.5, the attenuation and contrast enhancement pattern is uniform.

COMPUTED TOMOGRAPHIC DIAGNOSIS

- Destructive rhinitis
- Left sided otitis media

HOSPITAL NAME

Mobile Pet Imaging
CFL

INTERPRETATION OF THE FINDINGS & FURTHER RECOMMENDATIONS

The findings are consistent with chronic inflammatory rhinitis and emerging destruction of the nasal conchal structures. Viral rhinitis with bacterial superinfection is the most likely causative agents. However, early stages of mycotic superinfection (cryptococcal rhinitis) cannot be ruled out entirely.

REFERRING VET

Borecky Recommend rhinoscopy for further evaluation with sampling for culture and histopathology to rule out underlying fungal disease. Clinical signs may reoccur in chronic cases.

INVOICE

52718

The otitis media is considered as a sequela to upper airway infection, due to ascending infection by the Eustachian tube.

DATE

7-6-22



PATIENT

Mister Smeltzer

SPECIES

Feline

BREED

Savannah

SEX

MN

AGE

8 Years

INTERPRETED BY

Sebastian Schaub, DVM
Dr. med. vet. DipECVDI

HOSPITAL NAME

Mobile Pet Imaging
CFL

REFERRING VET

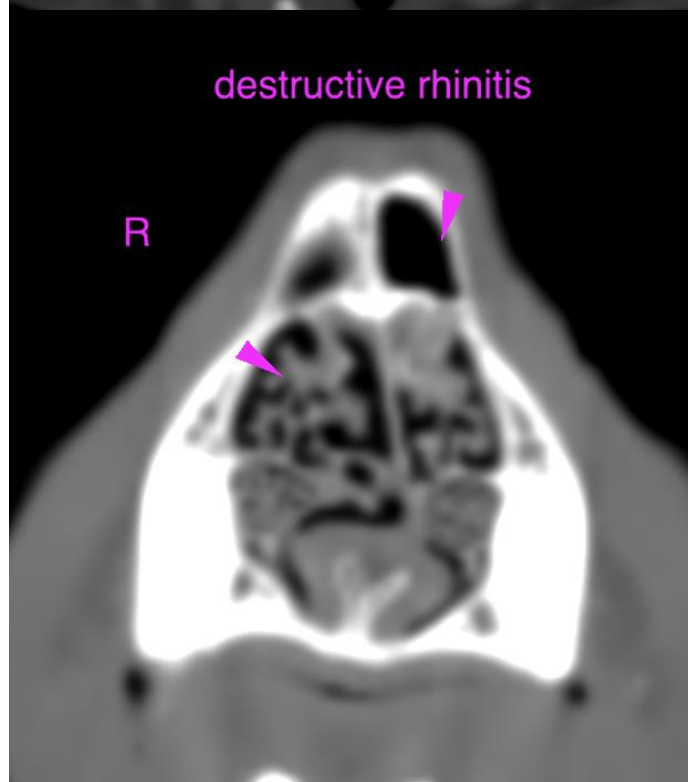
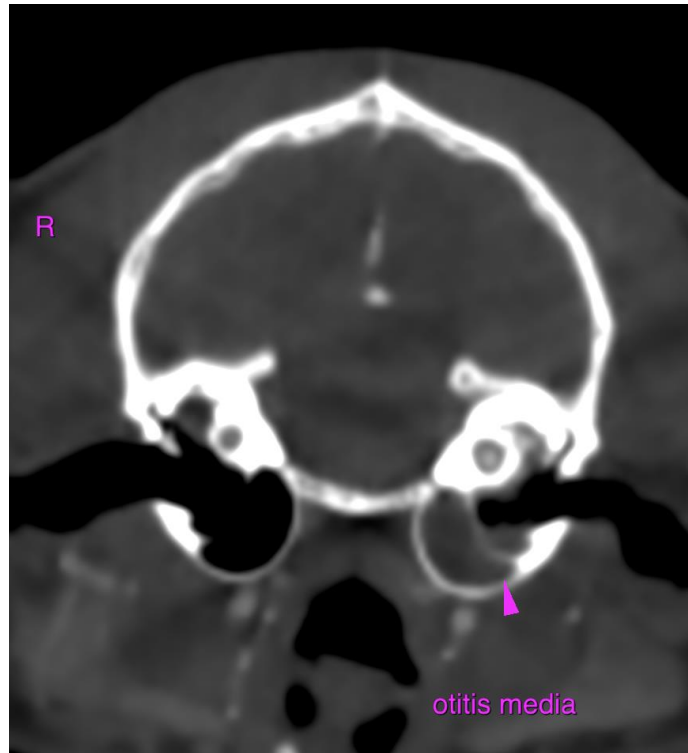
Borecky

INVOICE

52718

DATE

7-6-22





PATIENT

Mister Smeltzer

SPECIES

Feline

The information and recommendations provided are based on the images presented by the referring veterinarian/sonographer. No evaluation can be communicated regarding pathology that was not visible in the image/video clips provided.

BREED

Savannah

Thank you for this referral. If the clinical or image interpretation does not parallel your findings or if I can be of any further assistance please contact me.

Sebastian Schaub, Sebastian Schaub, DVM, Dr. med. vet. DipECVDI
sebast.schaub@gmail.com

SEX

MN

AGE

8 Years

INTERPRETED BY

Sebastian Schaub, DVM
Dr. med. vet. DipECVDI

HOSPITAL NAME

Mobile Pet Imaging
CFL

REFERRING VET

Borecky

INVOICE

52718

DATE

7-6-22