



PATIENT PRESENTING CLINICAL SIGNS

Theo Fontaine Losing weight, lethargic, distended abdomen, and only eating small amounts.
Abnormal PE/Chem/CBC/UA Results: Moderate anemia, leukopenia, mild increase in creatinine, otherwise unremarkable.

SPECIES RADIOGRAPHIC STUDY OF THE THORAX & ABDOMEN

Feline An overview study including the thorax and abdomen in three imaging planes is provided for review.

RADIOGRAPHIC FINDINGS

BREED Thorax

Domestic Shorthair In the pleural cavity, a significant amount of soft tissue material is appreciated. The lung lobes are retracted from the thoracic wall and present a decreased volume and generalized ground glass opacity. The cardiac silhouette is effaced by the soft tissue material in the pleural space.

SEX The osseous and surrounding soft tissue structures of the thorax present without abnormalities.

Male Neutered **Abdomen**

The surrounding bony structures are within normal limits.

AGE The abdomen is distended. The serosal detail is lost due to soft tissue material in the peritoneal space, effacing the margins of the abdominal organs. The gastrointestinal tract is generalized distended by gas.

12 Years

INTERPRETED BY RADIOGRAPHIC DIAGNOSIS

Sebastian Schaub, DVM
Dr. med. vet. DipECVDI

- Pleural effusion
- Peritoneal effusion

HOSPITAL NAME INTERPRETATION OF THE FINDINGS & FURTHER RECOMMENDATIONS

St. Catherine's Animal Hospital

The radiographic study is consistent with bicavitary effusion. An underlying cause cannot be specified by radiography as the effusion is silhouetting with the thoracic and abdominal anatomical structures. Differentials for the bicavitary effusion include pancreatitis, infection (e.g. FIP), inflammation (e.g. vasculitis), neoplasia (e.g. lymphosarcoma, mesothelioma), cardiac disease, hepatic disease, hypoproteinemia or trauma. Further workup warrants tapping the effusion and complete fluid analysis. An abdominal ultrasound and echocardiography can be used as advanced imaging modality as well.

REFERRING VET

Dr. Bekhit

INVOICE

59151

DATE

7-4-23



PATIENT

Theo Fontaine

SPECIES

Feline

BREED

Domestic Shorthair

SEX

Male Neutered

AGE

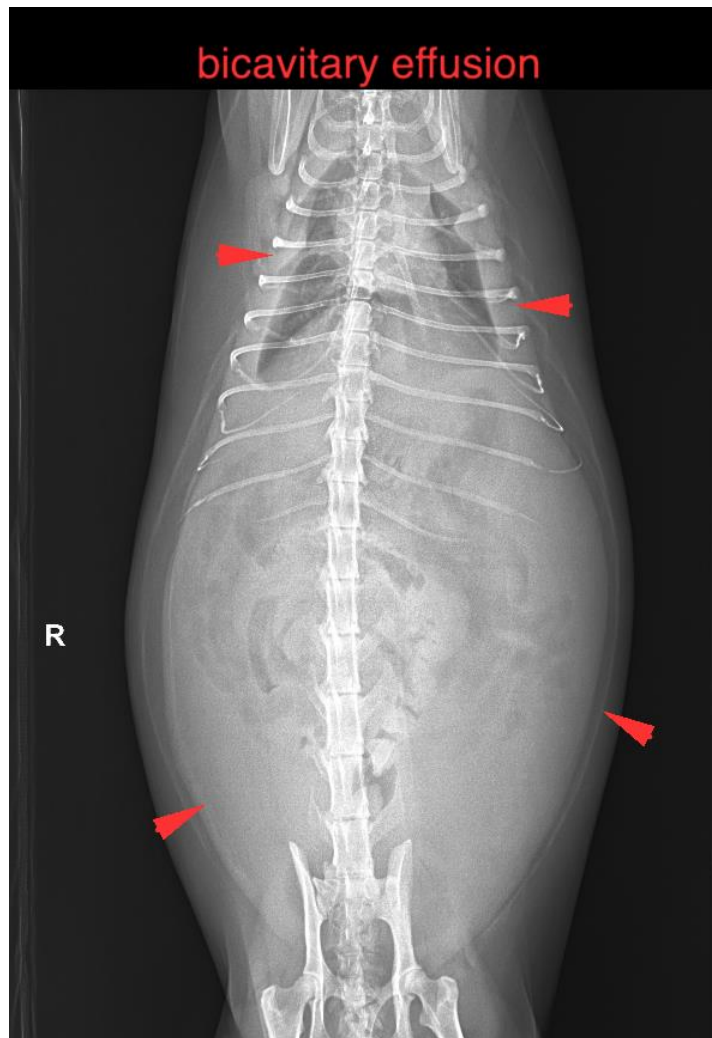
12 Years

INTERPRETED BY

Sebastian Schaub, DVM
Dr. med. vet. DipECVDI

HOSPITAL NAME

St. Catherine's Animal
Hospital



REFERRING VET

Dr. Bekhit

The information and recommendations provided are based on the images presented by the referring veterinarian/sonographer. No evaluation can be communicated regarding pathology that was not visible in the image/video clips provided.

INVOICE

59151

Thank you for this referral. If the clinical or image interpretation does not parallel your findings or if I can be of any further assistance please contact me.

Sebastian Schaub, Sebastian Schaub, DVM, Dr. med. vet. DipECVDI
info@sonopath.com

DATE

7-4-23