



PATIENT PRESENTING CLINICAL SIGNS

PATIENT
Panda Wang Lee

SPECIES
Canine

BREED
Siberian Husky

SEX
MN

AGE
9 Years

INTERPRETED BY
Sebastian Schaub, DVM
Dr. med. vet. DipECVDI

HOSPITAL NAME
Animal Health Partners

REFERRING VET
Lea Mehrkens

INVOICE
52677

DATE
7-4-22

May 18th, routine bloodwork routine bloodwork at RDVM showed marked lymphocytosis (confirmed with pathology review), mild elevation in ALT (152) and marked elevation ALP (1,953) Presented to IM service - Abdominal U/S June 17/22 revealed the right liver having a 5.41cm x 4.97cm mass compromised of numerous cysts and cavitations. Dorsal to this mass are few smaller cystic lesions (2.30cm x 2.48cm, 1.89cm x 1.82 cm). The spleen has numerous poorly defined hypoechoic nodules throughout it ("Swiss cheese" appearance), and is overall slightly large in size. CT performed of abdomen

COMPUTED TOMOGRAPHY OF THE ABDOMEN

A pre- and post-contrast CT study of the abdomen in a soft tissue reconstruction is provided for review.

COMPUTED TOMOGRAPHIC FINDINGS

The serosal fat presents normal attenuation behavior. There is no evidence of peritoneal effusion or peritonitis.

Both kidneys present within normal limits for size, shape and organ architecture. After contrast administration a bilaterally symmetric and uniform nephro- and pyelogram is noted.

The adrenal glands are within normal limits for size, shape and organ architecture.

The spleen presents with normal shape, even surface, uniformly attenuating parenchyma and homogeneous contrast enhancement, unremarkable.

Originating from the right lateral liver lobe, a spherical, heterogeneous soft tissue attenuating and contrast enhancing mass is visible, measuring 10.1 x 8.7 x 14.4 cm in size. Multiple fluid attenuating lesions are noted throughout the mass. The pylorus is deviated dorsally by the mass effect. The remainder of the hepatic parenchyma are uniform soft tissue attenuating with a mit heterogeneous contrast enhancement pattern in the arterial phase and homogeneous contrast enhancement pattern in the delayed post contrast phases. A small (<6 mm) parenchymal filling defect in the left division of the liver. The hepatic margins are smooth.

The left hepatic lymph node and the gastric lymph node are prominent and rounded.

The pancreas is evenly contoured, the pancreatic parenchyma is homogeneous and presents uniform contrast enhancement.

The position, delineation, wall and content of the gastrointestinal tract are considered within normal limits throughout.

The right transverse process of L7 is articulating with the sacroiliac joint

COMPUTED TOMOGRAPHIC DIAGNOSIS

- Solitary hepatic soft tissue mass right lateral liver lobe
- Lymphadenopathy left hepatic lymph node and gastric lymph node
- Solitary hepatic cyst



PATIENT

Panda Wang Lee

SPECIES

Canine

BREED

Siberian Husky

SEX

MN

AGE

9 Years

INTERPRETED BY

Sebastian Schaub, DVM
Dr. med. vet. DipECVDI

HOSPITAL NAME

Animal Health
Partners

REFERRING VET

Lea Mehrkens

INVOICE

52677

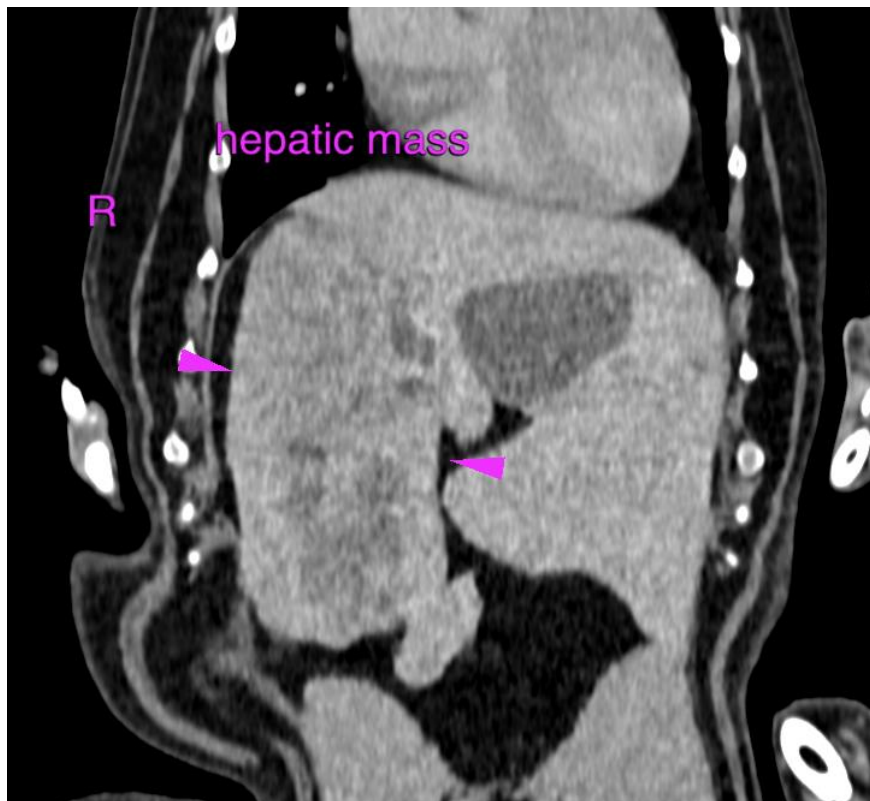
DATE

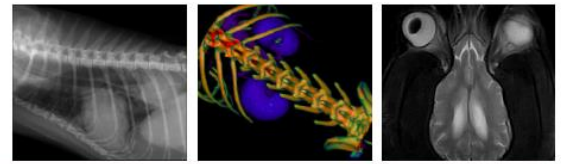
7-4-22

INTERPRETATION OF THE FINDINGS & FURTHER RECOMMENDATIONS

The CT study is consistent with the history of a hepatic mass, that appears to be fast growing given the ultrasound measurements. Differentials include hepatocellular carcinoma/adenoma, hemangiosarcoma, cholangiocellular carcinoma, round cell tumor, other. Complete surgical excision of the mass is considered feasible.

The prominent lymph nodes are equivocal for reactive hyperplasia or metastatic spread. Ultrasound guided FNA sampling or intraoperative FNA sampling or excision biopsy of the lymph nodes can be considered.





PATIENT

Panda Wang Lee

SPECIES

Canine

BREED

Siberian Husky

SEX

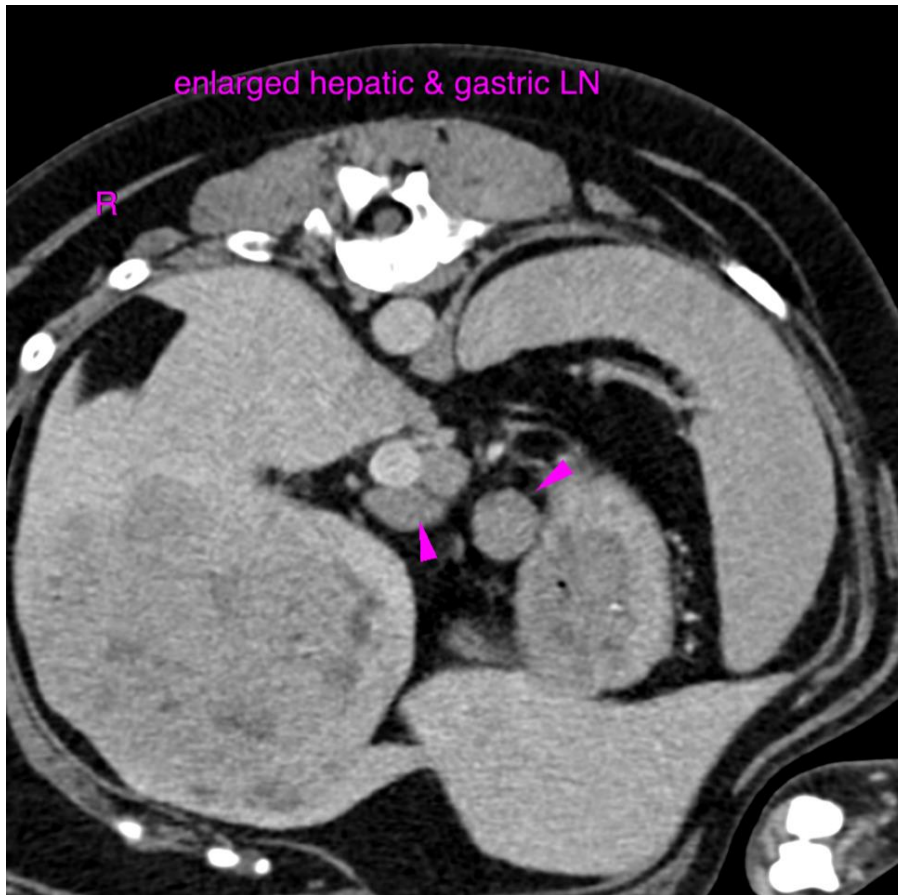
MN

AGE

9 Years

INTERPRETED BY

Sebastian Schaub, DVM
Dr. med. vet. DipECVDI



HOSPITAL NAME

Animal Health
Partners

REFERRING VET

Lea Mehrkens

INVOICE

52677

DATE

7-4-22

The information and recommendations provided are based on the images presented by the referring veterinarian/sonographer. No evaluation can be communicated regarding pathology that was not visible in the image/video clips provided.

Thank you for this referral. If the clinical or image interpretation does not parallel your findings or if I can be of any further assistance please contact me.

Sebastian Schaub, Sebastian Schaub, DVM, Dr. med. vet. DipECVDI
sebast.schaub@gmail.com