



PATIENT PRESENTING CLINICAL SIGNS

Nina Gan Came for annual checkup , Heart murmurs grade 3/6 was auscultate
Abnormal PE/Chem/CBC/UA Results: Grade 3/4 periodontal disease , Grade 3/5 heart murmurs ,
Bloodwork unremarkable , T4 WNL , 3 Views were sent to evaluate the heart.

SPECIES RADIOGRAPHIC STUDY OF THE THORAX

Feline Radiographs of the thorax in three imaging planes are provided for review.

BREED RADIOGRAPHIC FINDINGS

DSH The surrounding bony structures are within normal limits.

The extrathoracic soft tissues present homogeneous without abnormalities.

SEX The heart is of normal size and shape, there is no evidence of cardiac chamber or vascular enlargement. The pulmonary vasculature is within normal limits.

Female Spayed The trachea is normal in diameter and presents the anticipated course. The luminal outline of the trachea is smooth.

AGE The bronchial tree presents with thin walls and tapers uniformly towards the periphery as expected.

3 The lung parenchyma presents the expected architecture and opacity; the intrapulmonary vascular branching is seen up to the third order lung vessels. In the VD view, level with the 6th intercostal space, a curved soft tissue opacity is seen in superimposed on the periphery of the right cranial lung lobe

INTERPRETED BY

Sebastian Schaub, DVM
Dr. med. vet. DipECVDI

The diaphragm is well delineated with even surface and the expected mild cranial bulging of the diaphragmatic cupola.

HOSPITAL NAME RADIOGRAPHIC DIAGNOSIS

Lakeshore Woods
Animal Hospital

- Normal thorax but possible plate-like atelectasis right cranial lung lobe

INTERPRETATION OF THE FINDINGS & FURTHER RECOMMENDATIONS

REFERRING VET

Dr. Sam Masoud

The radiographic study of the thorax presents without abnormalities of the cardiovascular structures or lung parenchyma. Owing the clinically appreciated heart murmur, a cardiac echo would be ideal for further workup.

TECHNICAL COMMENTS

INVOICE

52680

Human fingers are seen in the primary beam, please consider radiation safety guidelines!

DATE

7-4-22



PATIENT

Nina Gan

SPECIES

Feline

BREED

DSH

SEX

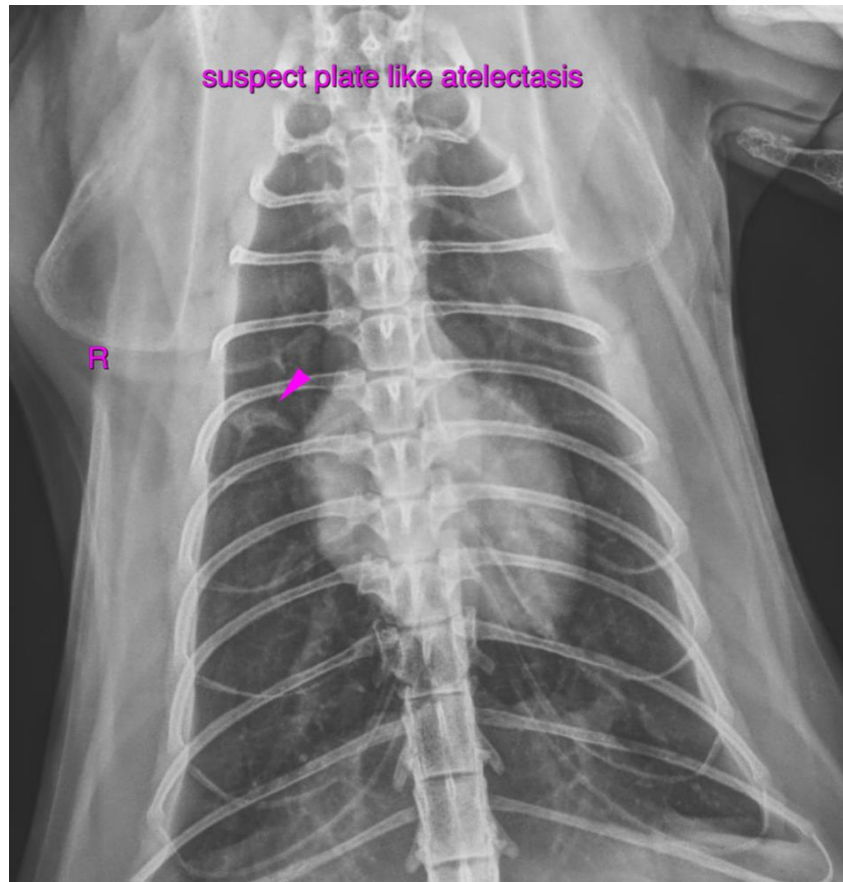
Female Spayed

AGE

3

INTERPRETED BY

Sebastian Schaub, DVM
Dr. med. vet. DipECVDI



HOSPITAL NAME

Lakeshore Woods
Animal Hospital

REFERRING VET

Dr. Sam Masoud

INVOICE

52680

DATE

7-4-22

The information and recommendations provided are based on the images presented by the referring veterinarian/sonographer. No evaluation can be communicated regarding pathology that was not visible in the image/video clips provided.

Thank you for this referral. If the clinical or image interpretation does not parallel your findings or if I can be of any further assistance please contact me.

Sebastian Schaub, Sebastian Schaub, DVM, Dr. med. vet. DipECVDI
sebast.schaub@gmail.com