



PATIENT PRESENTING CLINICAL SIGNS

Emmie Love Last night around 8pm Emmie vomited a bunch. At least 6 times. This morning she normally runs inside from the garage but she didn't today and she has been laying around all day. She did not eat or drink today. She walked would walk up to the water and look at the bowl and then walk away. Around 12pm she came out of her carrier and had diarrhea that looked bloody. She hunts various animals
SPECIES Abnormal PE/Chem/CBC/UA Results: PALE, CRT 2.5 seconds Painful, TENSE, no masses. Rectal examination not performed. TACHYCARDIC (200PBM). SMELLY, MESSY REAR END. Neurologic: QUIET, normal cranial nerve function. Oral: TACKY
 Feline

BREED RADIOGRAPHIC STUDY OF THE ABDOMEN

DMH Radiographs of the abdomen in three imaging planes are provided for review.

RADIOGRAPHIC FINDINGS

SEX The surrounding bony structures are within normal limits.
 FS No abnormalities of the extraabdominal soft tissues are noted. The abdominal wall is smooth and thin.
 The serosal detail is maintained throughout the peritoneal and retroperitoneal space.

AGE The liver is appropriate in position, size and presents uniform opacity.

6 Years The splenic head is in the anticipated position and within normal limits for size and opacity. The splenic body and tail are considered normal for position, size, shape and opacity.

INTERPRETED BY Sebastian Schaub, DVM
 Dr. med. vet. DipECVDI Both kidneys are seen and present with normal size, shape, delineation and opacity. The urinary bladder is in its anticipated position. No radiopaque calculi are noted throughout the upper and lower urinary tract.

The stomach is in its anticipated position and mild to moderately distended by fluid.

HOSPITAL NAME Elizabeth Animal Hospital
 The small intestinal loops are of even diameter and non-dilated, a small amount of gas is seen within the small intestinal loops and considered within normal limits.

The colon is seen in the expected position and mildly distended by fluid.

RADIOGRAPHIC DIAGNOSIS

- REFERRING VET** Leon Anderson, DVM
- Fluid filled stomach
 - Fluid filled colon

INTERPRETATION OF THE FINDINGS & FURTHER RECOMMENDATIONS

INVOICE 59590
 The fluid pattern of the gastrointestinal tract in combination with the presenting clinical signs is highly suggestive for underlying gastroenteritis – e.g. due to pancreatitis, parasitic infection, dietary indiscretion, other – and secondary functional gastric emptying disorder. There is no evidence of radiopaque foreign material, abnormal gas pattern or signs for gastrointestinal mechanical obstruction. If clinical signs are refractory to therapy, recommend follow up radiographs or a complete abdominal ultrasound examination.

DATE
 7-31-23



PATIENT

Emmie Love

SPECIES

Feline

BREED

DMH

SEX

FS

AGE

6 Years

INTERPRETED BY

Sebastian Schaub, DVM
Dr. med. vet. DipECVDI

HOSPITAL NAME

Elizabeth Animal
Hospital

REFERRING VET

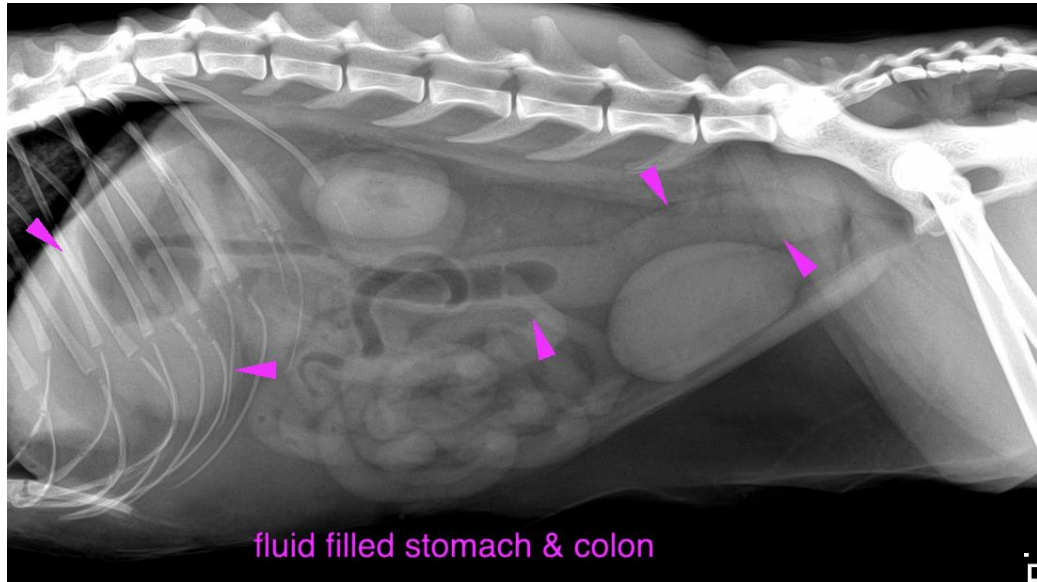
Leon Anderson, DVM

INVOICE

59590

DATE

7-31-23



The information and recommendations provided are based on the images presented by the referring veterinarian/sonographer. No evaluation can be communicated regarding pathology that was not visible in the image/video clips provided.

Thank you for this referral. If the clinical or image interpretation does not parallel your findings or if I can be of any further assistance please contact me.

Sebastian Schaub, Sebastian Schaub, DVM, Dr. med. vet. DipECVDI
info@sonopath.com