

**PATIENT**

Pixie Morriss

PRESENTING CLINICAL SIGNS

yelped when handled around neck/face area on monday, Tuesday, yelped when jumped up. Owner took to another vet, they didn't find anything, possible sore in TL area of spine. Send home on metacam, owner not sure if its helping, but the yelping is very sporadic. PE today, NSF

SPECIES

Canine

RADIOGRAPHIC STUDY OF THE CERVICAL & THORACIC SPINE

Radiographs of the thoracic & thoracic spine in two orthogonal imaging planes are provided for review.

BREED

Cavalier X

RADIOGRAPHIC FINDINGS

The osseous and surrounding soft tissue structures of the cervical spine are within normal limits.

The intervertebral disc space T3/T4 and T12/T13 is moderately narrowed. The remainder of the osseous and soft tissue.

SEX

MN

RADIOGRAPHIC DIAGNOSIS

- Discopathy T3/T4 and T12/T13
- Normal cervical spine

AGE

5

INTERPRETED BY

Sebastian Schaub, DVM
Dr. med. vet. DipECVDI

INTERPRETATION OF THE FINDINGS & FURTHER RECOMMENDATIONS

The narrowed IVD spaces indicate discopathy that might be associated with compressive myelopathy and can be a source for pain.

In case of strong suspicion for compressive myelopathy, recommend complementing workup by cross-sectional imaging.

HOSPITAL NAME

Barry Magill

REFERRING VET

Dr. Magill

INVOICE

53185

DATE

7-30-22



PATIENT

Pixie Morriss

SPECIES

Canine

BREED

Cavalier X

SEX

MN

AGE

5

INTERPRETED BY

Sebastian Schaub, DVM
Dr. med. vet. DipECVDI

HOSPITAL NAME

Barry Magill

REFERRING VET

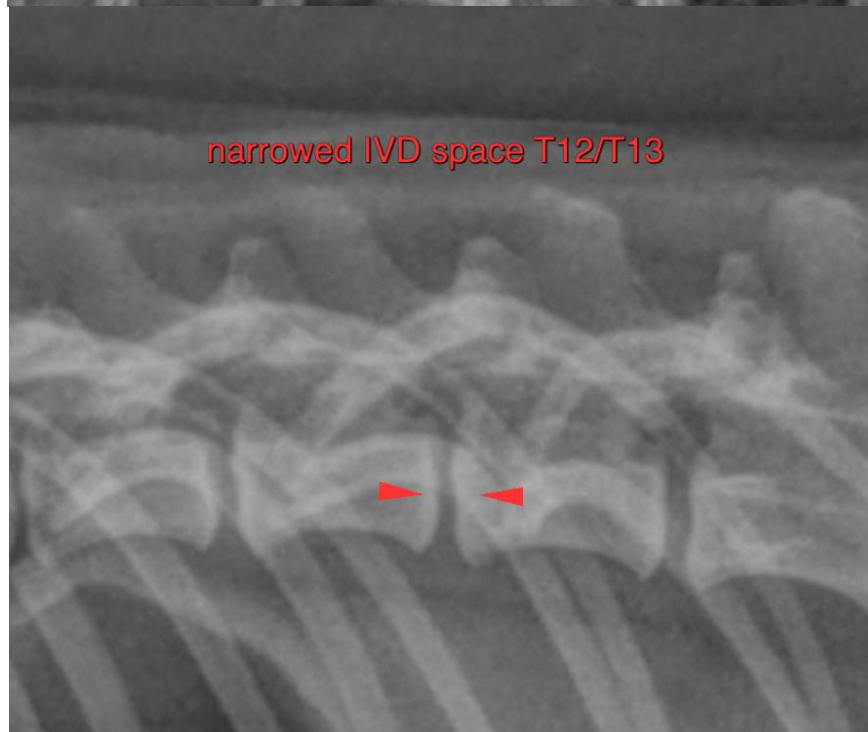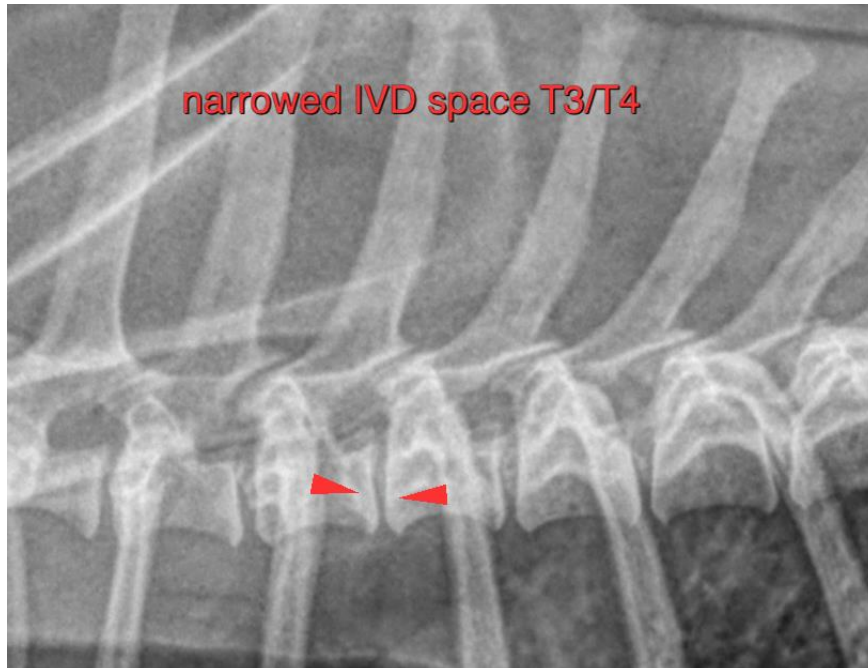
Dr. Magill

INVOICE

53185

DATE

7-30-22





PATIENT

Pixie Morriss

The information and recommendations provided are based on the images presented by the referring veterinarian/sonographer. No evaluation can be communicated regarding pathology that was not visible in the image/video clips provided.

SPECIES

Canine

Thank you for this referral. If the clinical or image interpretation does not parallel your findings or if I can be of any further assistance please contact me.

BREED

Cavalier X

Sebastian Schaub, Sebastian Schaub, DVM, Dr. med. vet. DipECVDI
sebast.schaub@gmail.com

SEX

MN

AGE

5

INTERPRETED BY

Sebastian Schaub, DVM
Dr. med. vet. DipECVDI

HOSPITAL NAME

Barry Magill

REFERRING VET

Dr. Magill

INVOICE

53185

DATE

7-30-22