



PATIENT PRESENTING CLINICAL SIGNS

Pumpkin Paterson O mentioned acute onset of lethargy and inappetance since yesterday. Does have another cat at home who is fine Nothing o can think of p getting into - but does like to lick grease off pans Was eating normal, no recent weight loss noted until this started Unsure of urine/BM habits - but dont think p has done it today. Backend seems dirty - once bladder? palpated, p dribbled some hematuric sample on towel Has vomited couple times yesterday

SPECIES

Feline

Abnormal PE/Chem/CBC/UA Results: Dull, sternal recumbancy Dehydration Lethargy Anorexia Suspect abnormal bladder Hypothermia UA - obtained as free catch due to abnormality of bladder pH 7, SG 1.023, WBC >50/hpf, RBC >50/hpf CBC - hemoconcentration (hct 0.63), mild lymphopenia Chemistry - Mod azotemia (BUN 20.6, creat 222), Hypocalcemia (1.53), mild hyperglycemia (7.7), elevated tBil (33) Lytes - mild hypochloremia (101), mild hyponatremia (106) Lipase - elevated 75.4

BREED

Domestic Shorthair

RADIOGRAPHIC STUDY OF THE ABDOMEN

Radiographs of the abdomen in three imaging planes are provided for review.

SEX

Female Spayed

RADIOGRAPHIC FINDINGS

The surrounding bony structures are within normal limits.

AGE

10 Years

No abnormalities of the extraabdominal soft tissues are noted. The abdominal wall is smooth and thin.

The serosal detail is mildly decreased and the peritoneal fat presents mild fat stranding.

The liver is appropriate in position, size and presents uniform opacity.

INTERPRETED BY

The splenic head is in the anticipated position and within normal limits for size and opacity.

Sebastian Schaub, DVM
Dr. med. vet. DipECVDI

The volume of the right kidney is mildly decreased in comparison to the left kidney. Both kidneys have mild irregular margins. The urinary bladder is in its anticipated position. At least 9 mineral opaque, roundish to irregular ovoid shaped calculi are superimposed on the urinary bladder, measuring up to 5 mm in diameter.

HOSPITAL NAME

The stomach is in its anticipated position and empty but a small amount of gas.

St. Catherine's Animal
Hospital

The small intestinal loops are of even diameter and non-dilated, a small amount of gas is seen within the small intestinal loops. A small intestinal loop in the ventral abdomen appears mildly corrugated.

REFERRING VET

The colon is seen in the expected position and nearly empty

Dr. Nozomi Murota

RADIOGRAPHIC DIAGNOSIS

INVOICE

59130

- Suspect mild peritoneal effusion
- Chronic nephropathy, R>L
- Suspect mild corrugation of the small intestinal tract
- Cystolithiasis

INTERPRETATION OF THE FINDINGS & FURTHER RECOMMENDATIONS

DATE

7-3-23

The appreciated soft tissue striation of the peritoneal fat indicates a small volume of peritoneal effusion; an underlying cause for the mild peritoneal effusion cannot be specified and transudate or exudate are considerations – e.g. secondary to pancreatitis, hepatic disease, renal disease, vasculitis, septic, other. Complementing workup by fpl is considered beneficial to check for underlying



PATIENT pumpkin Paterson
pancreatitis. Workup can be complemented by an abdominal ultrasound examination for further evaluation of the pancreas and tapping of the peritoneal effusion if applicable.

The mild corrugation of the small intestinal loops can be a sequela to peritoneal effusion, there are no specific imaging findings indicating underlying linear foreign body.

SPECIES

Feline

BREED

Domestic Shorthair

SEX

Female Spayed

AGE

10 Years

INTERPRETED BY

Sebastian Schaub, DVM
Dr. med. vet. DipECVDI

HOSPITAL NAME

St. Catherine's Animal
Hospital

REFERRING VET

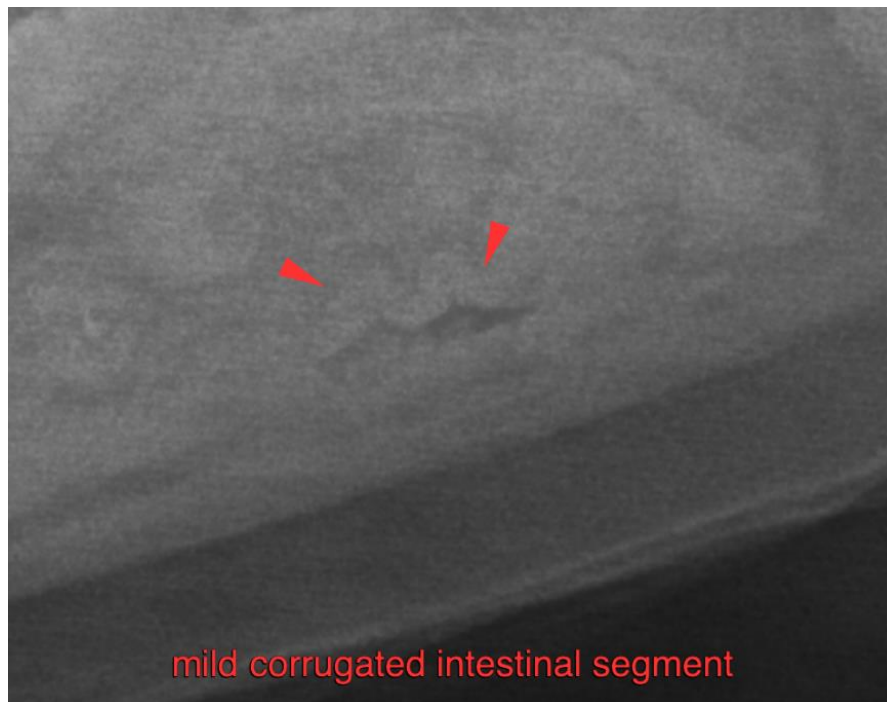
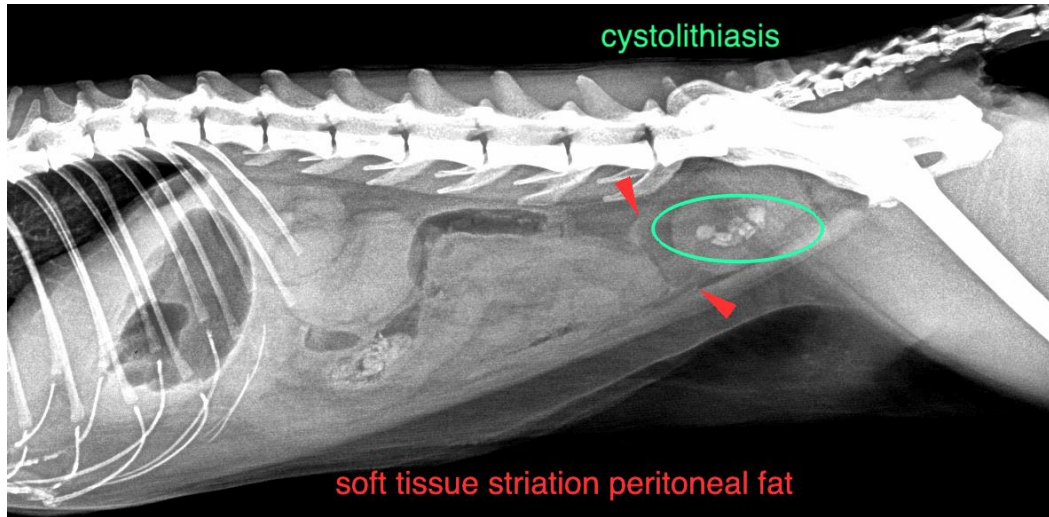
Dr. Nozomi Murota

INVOICE

59130

DATE

7-3-23





PATIENT

Pumpkin Paterson

SPECIES

Feline

The information and recommendations provided are based on the images presented by the referring veterinarian/sonographer. No evaluation can be communicated regarding pathology that was not visible in the image/video clips provided.

Thank you for this referral. If the clinical or image interpretation does not parallel your findings or if I can be of any further assistance please contact me.

BREED

Domestic Shorthair

Sebastian Schaub, Sebastian Schaub, DVM, Dr. med. vet. DipECVDI
info@sonopath.com

SEX

Female Spayed

AGE

10 Years

INTERPRETED BY

Sebastian Schaub, DVM
Dr. med. vet. DipECVDI

HOSPITAL NAME

St. Catherine's Animal
Hospital

REFERRING VET

Dr. Nozomi Murota

INVOICE

59130

DATE

7-3-23