



PATIENT PRESENTING CLINICAL SIGNS

Jake Peron Patient presented today for coughing for the past month (owner stated that it subsided for 3-4 days). - Multiple nodules present over the body -Gums look good - patient had severe periodontal disease and all teeth were extracted 1/29/21 -Grade II - III heart murmur - first noted today -Labored breathing upon exam /work-up T: 103.2 P: 120 R: 35 Weight today: 13 lbs 14.5 oz Weight 1/16/23: 14 lbs 8 oz
SPECIES Abnormal PE/Chem/CBC/UA Results: Blood Pressure Readings: (1.) 66 / 51 map: 55 bpm: 91 (2.) 104 / 73 map: 80 bpm: 188 (3.) 120 / 87 map: 96 bpm: 134 (4.) 57 / 44 map: 47 bpm: 136
 Canine HWT/Lyme/EH/AP Test: Negative X 4 - 1/7/23 ProCyte: RETIC-HGB: 21.9 (Norm: 22.3 to 29.6) WBC: 35.39 (Norm: 5.05 to 16.76) NEU: 28.95 (Norm: 2.95 to 11.64) MONO: 2.25 (Norm: 0.16 to 1.12)
BREED BASO: 0.12 (Norm: 0.00 to 0.10) PLT: 677 (Norm: 148 to 484) PCT: 0.84 (Norm: 0.14 to 0.46) All Else WNL Catalyst: GLOB: 4.9 (Norm: 2.5 to 4.5) All Else WNL Radiographs (left and right lateral, d/v thorax) - included - Area of concern right caudal lung lobe Blood Pressure (included)
 Shih Tzu/Bichon

RADIOGRAPHIC STUDY OF THE THORAX

SEX Radiographs of the thorax in three imaging planes are provided for review.

MN RADIOGRAPHIC FINDINGS

Multifocal mild spondylosis formation is seen along the caudal thoracic spine.

AGE The extrathoracic soft tissues present homogeneous without abnormalities.

15 Years The heart is of normal size and shape, there is no evidence of cardiac chamber or vascular enlargement. The pulmonary vasculature is within normal limits.

INTERPRETED BY

The cranial mediastinum presents the expected soft tissue opacity. The mediastinal width is less than twice the width of the vertebral column at the same level.

The trachea is normal in diameter and presents the anticipated course. The luminal outline of the trachea is smooth.

Sebastian Schaub, DVM
 Dr. med. vet. DipECVDI

HOSPITAL NAME

The right caudal lung lobe is consolidated, accentuating the margins of the respective lung lobe and the volume of the right caudal lung lobe is maintained to mildly increased. The first degree bronchus of the right caudal lung lobe is deviated ventrally and laterally in the hilar region and compressed in the caudal segments. The principal bronchi are deviated ventrally. The remainder of the hepatic parenchyma are aerated and present the expected architecture.

Harveys Lake
 Veterinary Clinic

REFERRING VET

The diaphragm is well delineated with even surface and the expected mild cranial bulging of the diaphragmatic cupola.

John Bucha VMD

RADIOGRAPHIC DIAGNOSIS

INVOICE

- Consolidated right caudal lung lobe with maintained to mildly increased volume and mass effect on the respective bronchi
- Spondylosis deformans

59120

INTERPRETATION OF THE FINDINGS & FURTHER RECOMMENDATIONS

DATE

The pulmonary mass of the right caudal lung lobe is highly suggestive for pulmonary neoplastic transformation, carcinoma is most common. (Ultrasound guided) FNA sampling of the right caudal lung lobe via the 7th/8th right intercostal space can be performed to confirm the diagnosis. If surgical management is an option, workup can be complemented by a CT study of the thorax for surgical

7-3-23



PATIENT planning.

Jake Peron

SPECIES

Canine

BREED

Shih Tzu/Bichon

SEX

MN

AGE

15 Years

INTERPRETED BY

Sebastian Schaub, DVM
Dr. med. vet. DipECVDI

HOSPITAL NAME

Harveys Lake
Veterinary Clinic

REFERRING VET

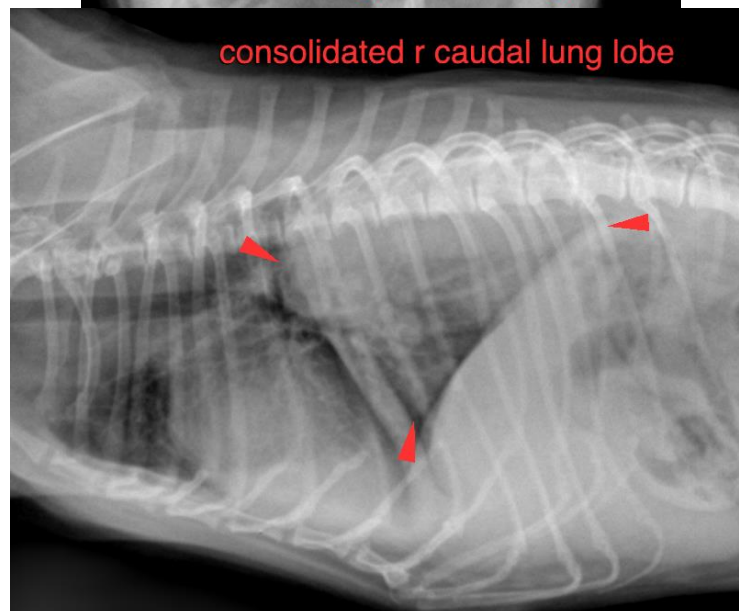
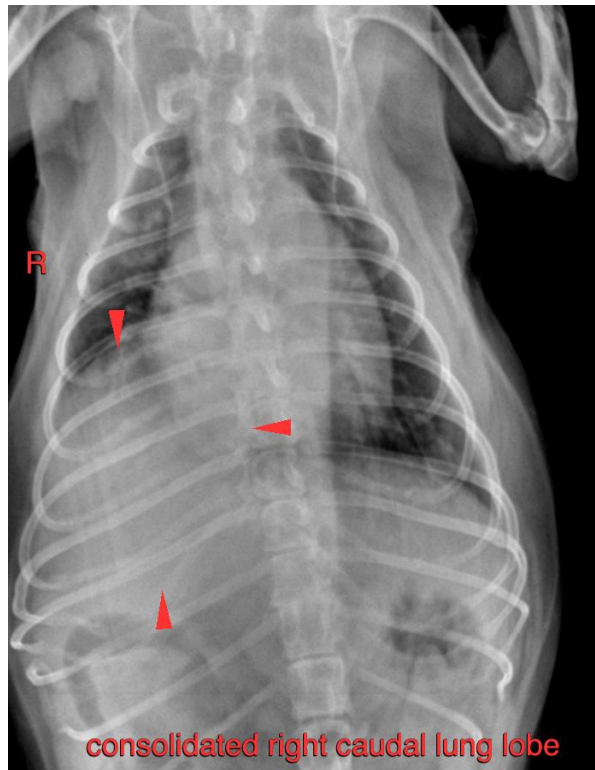
John Bucha VMD

INVOICE

59120

DATE

7-3-23





PATIENT

Jake Peron

The information and recommendations provided are based on the images presented by the referring veterinarian/sonographer. No evaluation can be communicated regarding pathology that was not visible in the image/video clips provided.

SPECIES

Canine

Thank you for this referral. If the clinical or image interpretation does not parallel your findings or if I can be of any further assistance please contact me.

BREED

Shih Tzu/Bichon

Sebastian Schaub, Sebastian Schaub, DVM, Dr. med. vet. DipECVDI
info@sonopath.com

SEX

MN

AGE

15 Years

INTERPRETED BY

Sebastian Schaub, DVM
Dr. med. vet. DipECVDI

HOSPITAL NAME

Harveys Lake
Veterinary Clinic

REFERRING VET

John Bucha VMD

INVOICE

59120

DATE

7-3-23