



PATIENT PRESENTING CLINICAL SIGNS

Luna Moreno History: Survey study of the spine
Abnormal PE/Chem/CBC/UA Results: Ambulatory x 4, aggressive (limited exam)

SPECIES COMPUTED TOMOGRAPHIC STUDY OF THE THORACIC & LUMBAR SPINE

Canine A high resolution pre- and post-contrast CT study of the thoracic and lumbar spine is provided for review.

BREED COMPUTED TOMOGRAPHIC FINDINGS

French Bulldog THE LAST RIB BEARING VERTEBRA IS COUNTED AS T13.

SEX

Multiple intervertebral discs of the caudal thoracic spine and the lumbar spine present moderate central mineralization.

Spayed Female L4 presents as hemivertebra.

AGE

4 Years

Level with the intervertebral disc space L1/L2, mild heterogeneous hyperattenuating material is seen in the left ventral aspect of the vertebral canal, occupying approximately up to 20% of the cross-sectional area of the vertebral canal at the same level; the material is extending up to the respective vertebral endplates. The dural tube level L1/L2 is mildly distorted.

INTERPRETED BY

Sebastian Schaub, DVM
Dr. med. vet. DipECVDI

The intervertebral discs L3/L4 and L4/L5 are mildly bulging into the vertebral canal, distorting the ventral epidural space at the same level.

Congenital malformation of the sacrum with hemivertebra formation is seen.

HOSPITAL NAME

Mobile Pet Imaging

COMPUTED TOMOGRAPHIC DIAGNOSIS

- Intervertebral disc protrusion L1/L2 with compressive myelopathy
- Mild intervertebral discs protrusion L3/L4 and L4/L5 with possible dynamic compressive myelopathy
- Hemivertebra L4 and sacrum
- Multifocal chondroid disc degeneration along the thoracic and lumbar spine

REFERRING VET

Meaux

INTERPRETATION OF THE FINDINGS & FURTHER RECOMMENDATIONS

INVOICE

16624

The main finding is the intervertebral disc protrusion L1/L2 with likely compressive myelopathy – a potential source for pain. Depending on the presenting clinical signs, conservative management is considered as the therapy of choice at this point and reevaluation of the patient is recommended if neurological deficits develop.

DATE

7/29/22



PATIENT

Luna Moreno

SPECIES

Canine

BREED

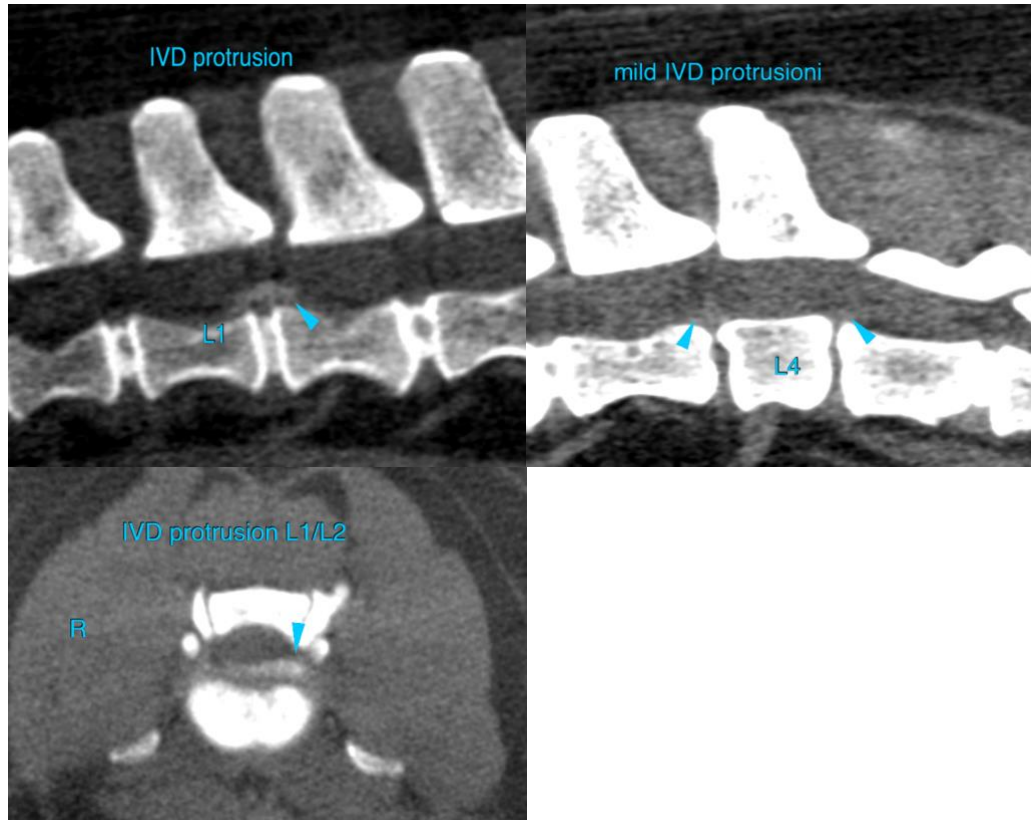
French Bulldog

SEX

Spayed Female

AGE

4 Years



INTERPRETED BY

Sebastian Schaub, DVM
Dr. med. vet. DipECVDI

The information and recommendations provided are based on the images presented by the referring veterinarian/sonographer. No evaluation can be communicated regarding pathology that was not visible in the image/video clips provided.

HOSPITAL NAME

Mobile Pet Imaging

Thank you for this referral. If the clinical or image interpretation does not parallel your findings or if I can be of any further assistance please contact me.

Sebastian Schaub, Sebastian Schaub, DVM, Dr. med. vet. DipECVDI
sebast.schaub@gmail.com

REFERRING VET

Meaux

INVOICE

16624

DATE

7/29/22