



PATIENT PRESENTING CLINICAL SIGNS

Pepper Ayoub History: As per owner, he would not eat this morning, only treats and drinking a little. Vomiting bile 3 times today. Need to rule out foreign body vs gastroenteritis.

SPECIES RADIOGRAPHIC STUDY OF THE ABDOMEN

Canine Radiographs of the abdomen in three imaging planes are provided for review.

RADIOGRAPHIC FINDINGS

BREED
Havanese The surrounding bony structures are within normal limits.
No abnormalities of the extraabdominal soft tissues are noted. The abdominal wall is smooth and thin.

SEX
Male The serosal detail is maintained throughout the peritoneal and retroperitoneal space.

The liver is appropriate in position, size and presents uniform opacity.
AGE
13 Weeks The splenic head is in the anticipated position and within normal limits for size and opacity. The splenic body and tail are considered normal for position, size, shape and opacity.

INTERPRETED BY
Sebastian Schaub, DVM Dr. med. vet. DipECVDI Both kidneys are seen and present with normal size, shape, delineation and opacity. The urinary bladder is in its anticipated position. No radiopaque calculi are noted throughout the upper and lower urinary tract.

HOSPITAL NAME
Truscott AH The stomach is in its anticipated position and significantly distended by fluid and small amount of gas.
The small intestinal loops are of even diameter and non-dilated, a small amount of gas is seen within the small intestinal loops and considered within normal limits.

RADIOGRAPHIC DIAGNOSIS

- REFERRING VET**
Medhat Meawad
- Gastric emptying disorder with fluid distended stomach
 - Empty intestinal tract, including the colon

INTERPRETATION OF THE FINDINGS & FURTHER RECOMMENDATIONS

INVOICE
23704 The fluid distended stomach indicates gastric emptying disorder. There is no evidence of radiopaque foreign material, abnormal gas pattern or signs for intestinal mechanical obstruction and the odds for functional gastric emptying disorder due to gastritis are considered high. If clinical signs are refractory to therapy, recommend follow up radiographs or a complete abdominal ultrasound examination.

DATE
7/28/23



PATIENT

Pepper Ayoub

SPECIES

Canine

BREED

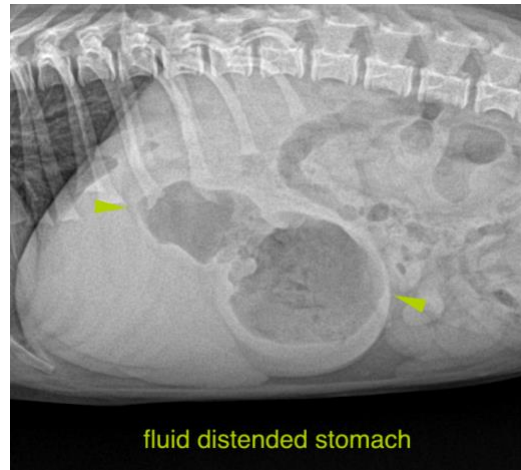
Havanese

SEX

Male

AGE

13 Weeks



The information and recommendations provided are based on the images presented by the referring veterinarian/sonographer. No evaluation can be communicated regarding pathology that was not visible in the image/video clips provided.

Thank you for this referral. If the clinical or image interpretation does not parallel your findings or if I can be of any further assistance please contact me.

INTERPRETED BY

Sebastian Schaub,
DVM Dr. med. vet.
DipECVDI

Sebastian Schaub, Sebastian Schaub, DVM, Dr. med. vet. DipECVDI
info@sonopath.com

HOSPITAL NAME

Truscott AH

REFERRING VET

Medhat Meawad

INVOICE

23704

DATE

7/28/23