



**PATIENT PRESENTING CLINICAL SIGNS**

Ophelia Pomeroy Recent dental float with marked disease of teeth, sending for further necessary extractions. hx of lethargy.

**SPECIES COMPUTED TOMOGRAPHIC STUDY OF THE SKULL**

Rabbit A high resolution pre- and post-contrast CT study of the skull is provided for review.

**COMPUTED TOMOGRAPHIC FINDINGS**

**BREED**

Dwarf Netherland

Triadan 106 & 206 present an elongated crown that is bending laterally. Triadan 107 & 207 present moderate retrograde growth of the roots; the roots of triadan 107 & 207 present resorptive lesions and ankylosis. The remaining maxillary buccal teeth present a retrograde dental growth Triadan 307 is absent. A remnant of the crown of triadan 308 is seen as well as a retained root of triadan 308 within the alveolar bone, presenting advanced ankylosis and resorptive lesions. Triadan 309 and 310 present moderate retrograde growth of the roots – perforating the alveolar crest in the apical region. Triadan 407 presents moderate retrograde growth of the root and abnormal lingual bending and loss of the hypoattenuating striation. Triadan 408 presents advanced resorptive lesions. Triadan 409 presents a loss of the hypoattenuating striation and retrograde growth of the root. Triadan 410 presents a retrograde growth of the root. Triadan 411 is absent.

**SEX**

Male

**AGE**

2 Years

The nasal cavity presents the expected aerated spaces between thin & even conchae and turbinates with smooth mucosal lining.

**INTERPRETED BY**

Sebastian Schaub,  
DVM Dr. med. vet.  
DipECVDI

Both temporomandibular joints present congruent joint spaces with even subchondral bone surfaces and are considered within normal limits.

Both tympanic bullae are aerated, the mucosal lining is not seen, the bony wall is smooth and thin. The external ear canals are within normal limits.

**HOSPITAL NAME**

Aloha Pet & Bird

The submandibular and medial retropharyngeal lymph nodes are small and elongated with a normal short-to-long-axis-ratio is < 0.5, the attenuation and contrast enhancement pattern is uniform.

**COMPUTED TOMOGRAPHIC DIAGNOSIS**

**REFERRING VET**

Dr. Hill

- Retrograde dental growth 107-110, 207-210, 309, 310, 407, 410 and 411
- Elongation and buccal deviation crowns of triadan 106 & 206
- Advanced root resorption and ankylosis 107, 308 and 408
- Dysplasia of triadan 407 and 409
- Absent triadan 307 and 411

**INVOICE**

23701

**INTERPRETATION OF THE FINDINGS & FURTHER RECOMMENDATIONS**

The CT study presents signs of generalized dental disease of the premolar and molar teeth – at this point dental examination ± correction on a regular basis appears beneficial.

**DATE**

7/28/23



**PATIENT**

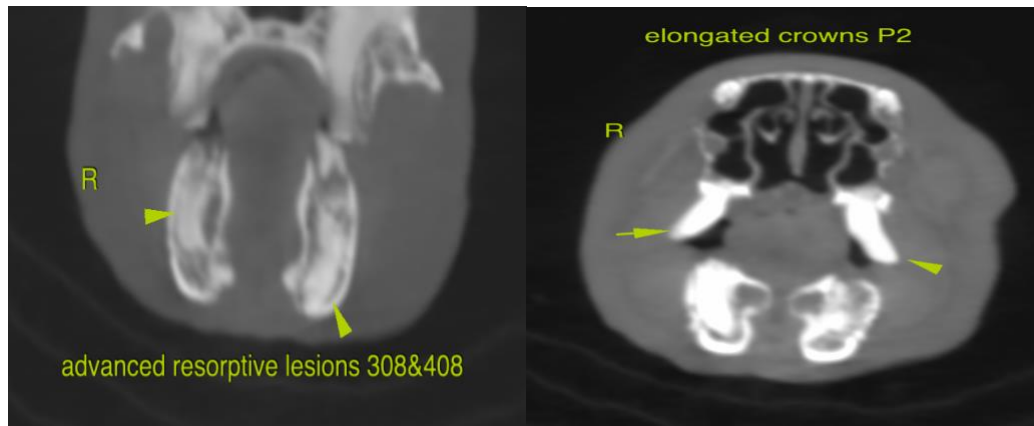
Ophelia Pomeroy

**SPECIES**

Rabbit

**BREED**

Dwarf Netherland



**SEX**

Male

**The information and recommendations provided are based on the images presented by the referring veterinarian/sonographer. No evaluation can be communicated regarding pathology that was not visible in the image/video clips provided.**

**AGE**

2 Years

Thank you for this referral. If the clinical or image interpretation does not parallel your findings or if I can be of any further assistance please contact me.

**Sebastian Schaub**, Sebastian Schaub, DVM, Dr. med. vet. DipECVDI  
info@sonopath.com

**INTERPRETED BY**

Sebastian Schaub,  
DVM Dr. med. vet.  
DipECVDI

**HOSPITAL NAME**

Aloha Pet & Bird

**REFERRING VET**

Dr. Hill

**INVOICE**

23701

**DATE**

7/28/23