



PATIENT PRESENTING CLINICAL SIGNS

Laika Leon Acute onset paraparesis about 6 weeks ago. Treated medically and with acupuncture (initially responded) but has progressed to Schiff Sherrington signs. Pet is unable to stand. Hx of pyometra in the past with splenectomy.

SPECIES COMPUTED TOMOGRAPHY OF THE THORACIC & LUMBAR SPINE

Canine A high resolution CT study of the thoracic & lumbar spine is provided for review.

COMPUTED TOMOGRAPHIC FINDINGS

BREED Multifocal along the thoracic & lumbar spine, moderate spondylosis formation is seen. The intervertebral discs of the thoracic spine are mildly bulging into the vertebral canal, distorting the ventral epidural space at the same level.

German Shepherd

SEX Multifocal throughout the epaxial musculature along the thoracic & lumbar spine, abdominal wall and shoulder musculature bilaterally, contrast enhancing nodular lesions of variable size are seen.

Spayed Female

The lung parenchyma presents with an innumerable amount of variable sized, well-defined soft tissue attenuating nodular lesions.

AGE

12 Years

The liver is irregularly enlarged and has an irregular contrast enhancement pattern.

COMPUTED TOMOGRAPHIC DIAGNOSIS

- Multiple contrast enhancing nodular lesions throughout the axial and appendicular musculature
- Irregular hepatic enlargement with heterogeneous contrast enhancement pattern.
- Structured nodular interstitial lung pattern
- Generalized advanced degenerative changes along the thoracic & lumbar spine

INTERPRETED BY

Sebastian Schaub, DVM
Dr. med. vet. DipECVDI

INTERPRETATION OF THE FINDINGS & FURTHER RECOMMENDATIONS

HOSPITAL NAME

Mobile Pet Imaging

The CT study is consistent with disseminated neoplastic disease with muscular, pulmonary and hepatic lesions – suspect hemangiosarcoma or carcinomatosis.

No lesion of the spine can be specified, explaining the acute onset of paraparesis, however ischemic myelopathy or metastatic disease are considerations.

REFERRING VET

Meaux

Unfortunately, the prognosis is infaust.

INVOICE

53171

DATE

7-28-22



PATIENT

Laika Leon

SPECIES

Canine

BREED

German Shepherd

SEX

Spayed Female

AGE

12 Years

INTERPRETED BY

Sebastian Schaub, DVM
Dr. med. vet. DipECVDI

HOSPITAL NAME

Mobile Pet Imaging

REFERRING VET

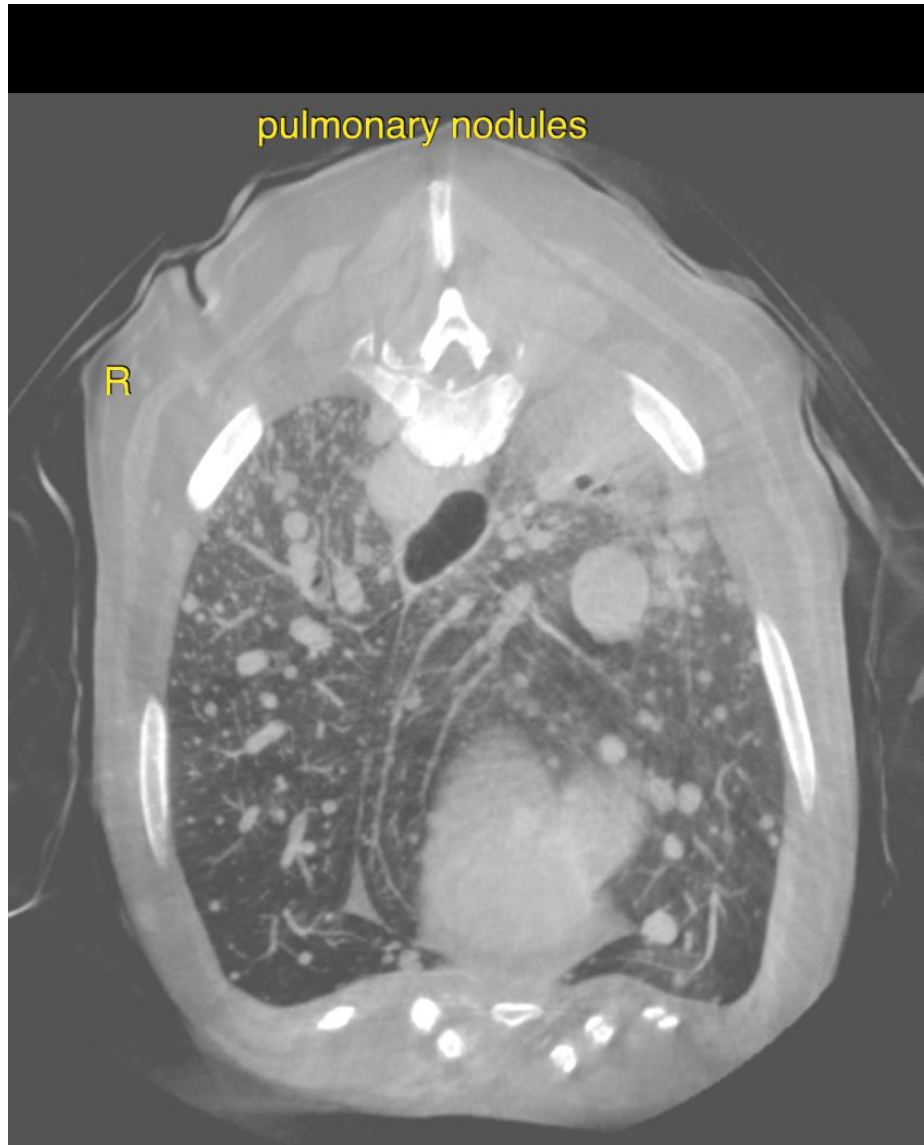Meaux

INVOICE

53171

DATE

7-28-22





PATIENT

Laika Leon

SPECIES

Canine

BREED

German Shepherd

SEX

Spayed Female

AGE

12 Years

INTERPRETED BY

Sebastian Schaub, DVM
Dr. med. vet. DipECVDI

HOSPITAL NAME

Mobile Pet Imaging

REFERRING VET

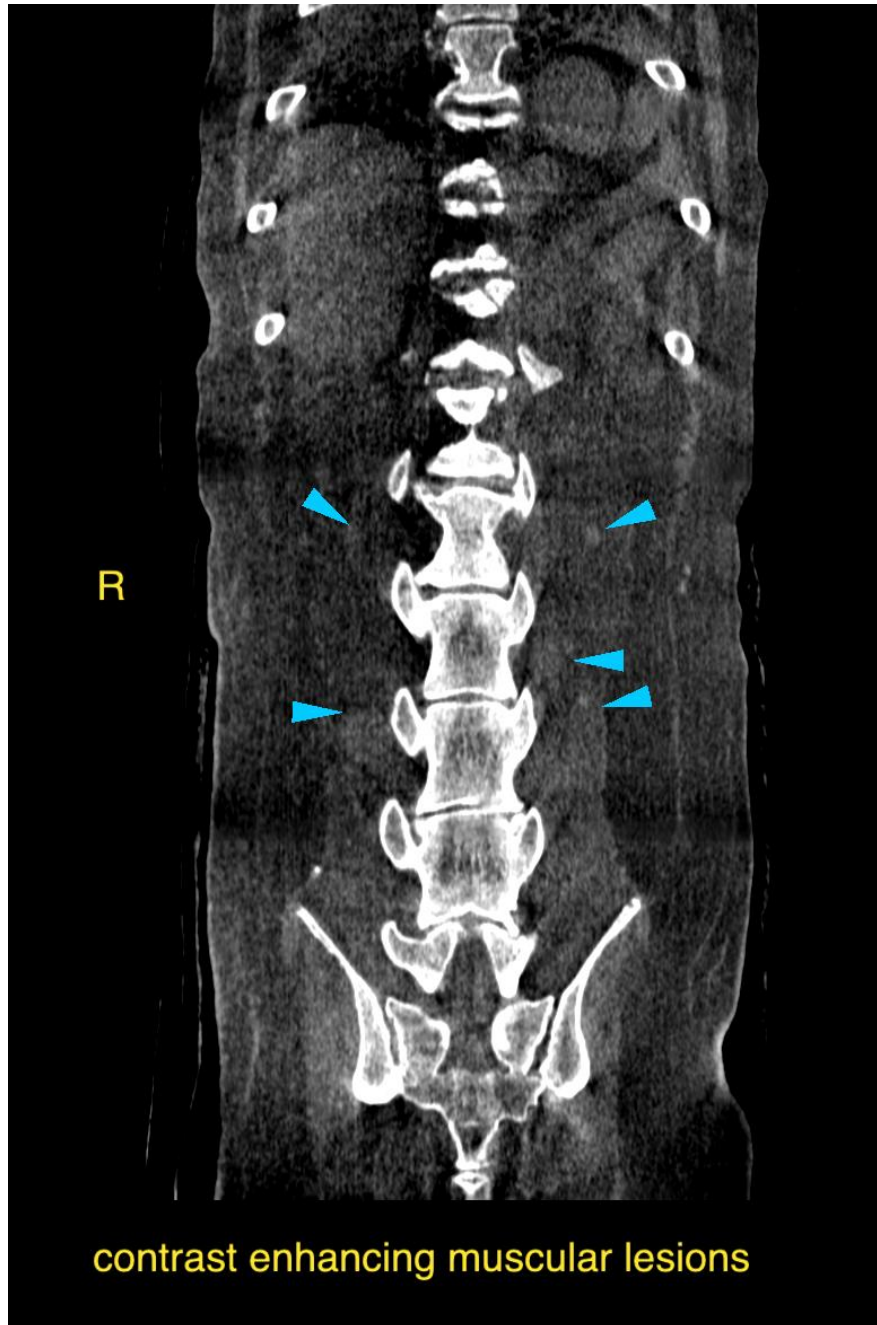
Meaux

INVOICE

53171

DATE

7-28-22





PATIENT

Laika Leon

SPECIES

Canine

BREED

German Shepherd

SEX

Spayed Female

AGE

12 Years

INTERPRETED BY

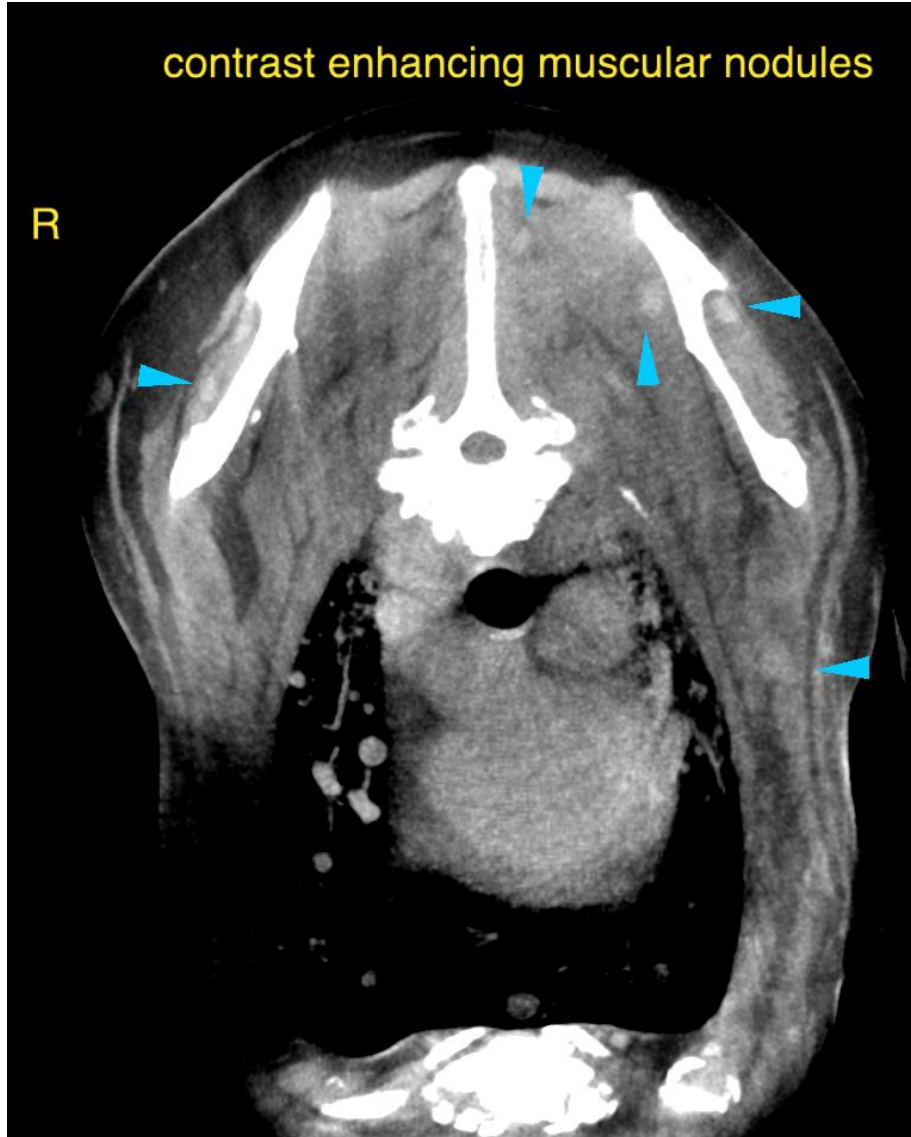
Sebastian Schaub, DVM
Dr. med. vet. DipECVDI

HOSPITAL NAME

Mobile Pet Imaging

REFERRING VET

Meaux



INVOICE

53171

The information and recommendations provided are based on the images presented by the referring veterinarian/sonographer. No evaluation can be communicated regarding pathology that was not visible in the image/video clips provided.

Thank you for this referral. If the clinical or image interpretation does not parallel your findings or if I can be of any further assistance please contact me.

DATE

7-28-22

Sebastian Schaub, Sebastian Schaub, DVM, Dr. med. vet. DipECVDI
sebast.schaub@gmail.com