



PATIENT

Kai Harvey

PRESENTING CLINICAL SIGNS

Wobbly and sore in hind legs. Scuffs toes also. ? Degenerative myelitis

SPECIES

Canine

COMPUTED TOMOGRAPHY OF THE THORACIC & LUMBAR SPINE

A plain and myelographic CT study of the thoracic & lumbar spine in a bone and soft tissue reconstruction is provided for review.

BREED

German Shepherd

The osseous and soft tissue structures of the pictured parts of the thoracic spine and the entire lumbar spine are within normal limits.

SEX

Neutered Male

After intrathecal contrast administration, the contrast media is located in the epidural space – no extradural compressive material is appreciated.

In the subcutaneous tissue at the left lateral aspect of T11, a well-defined subcutaneous nodule is seen, measuring 7 mm in diameter.

AGE

4 Years

COMPUTED TOMOGRAPHIC DIAGNOSIS

- Normal thoracic & lumbar spine

INTERPRETATION OF THE FINDINGS & FURTHER RECOMMENDATIONS

The CT study of the spine presents no macromorphological abnormality, explaining the presenting clinical signs. Depending on the development of clinical signs – chronic versus acute onset – acute non-compressive nucleus pulposus extrusion, ischemic myelopathy or degenerative myelopathy are considerations here. In case of doubt, an MRI study of the spine can be used as advanced imaging modality.

INTERPRETED BY

Sebastian Schaub, DVM
Dr. med. vet. DipECVDI

HOSPITAL NAME

Adelaide Plains
Veterinary Surgery

REFERRING VET

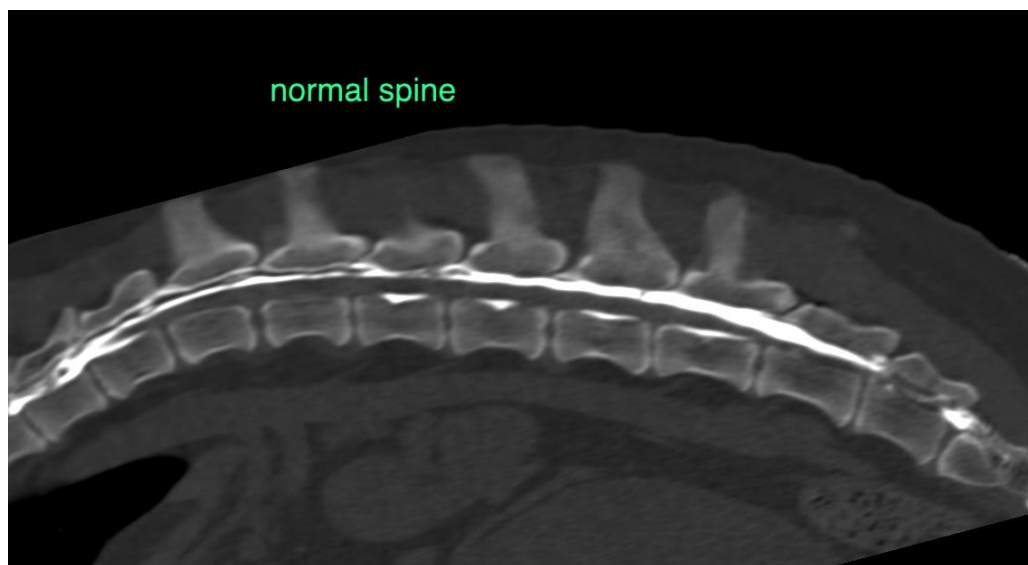
John Katakasi

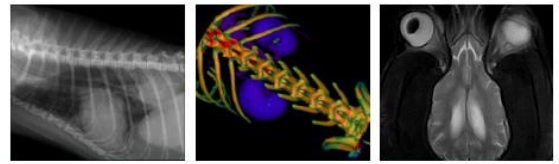
INVOICE

53140

DATE

7-28-22





PATIENT

Kai Harvey

SPECIES

Canine

The information and recommendations provided are based on the images presented by the referring veterinarian/sonographer. No evaluation can be communicated regarding pathology that was not visible in the image/video clips provided.

BREED

German Shepherd

Thank you for this referral. If the clinical or image interpretation does not parallel your findings or if I can be of any further assistance please contact me.

Sebastian Schaub, Sebastian Schaub, DVM, Dr. med. vet. DipECVDI
sebast.schaub@gmail.com

SEX

Neutered Male

AGE

4 Years

INTERPRETED BY

Sebastian Schaub, DVM
Dr. med. vet. DipECVDI

HOSPITAL NAME

Adelaide Plains
Veterinary Surgery

REFERRING VET

John Katakasi

INVOICE

53140

DATE

7-28-22