

**PATIENT**

Josie Finnen

PRESENTING CLINICAL SIGNS

LAMENESS ON RIGHT HIND LEG . PAIN IS DETECTED IN RIGHT STIFLE JOINT. DRAWER SIGN .

SPECIES

Canine

RADIOGRAPHIC STUDY OF THE STIFLE JOINTS

Radiographs of both stifle joints in two orthogonal imaging planes are provided for review.

BREED

Havanese

In the radiographic study with the time code 11:56, the patella is in a relative medial position, superimposed on the medial femoral condyle – not appreciated in the radiographic study with the time code 12:02.

SEX

Spayed Female

The periarticular bones of both stifle joints present mild osteophyte new bone formation, R>L. Both stifle joints present with mild to moderate intracapsular soft tissue swelling, R>L. Mild cranial subluxation of the right tibia is visible.

AGE

11 Years

RADIOGRAPHIC DIAGNOSIS

- Mild degenerative osteoarthritis stifle joints bilaterally, R>L
- Articular swelling stifle joints bilaterally, R>L
- Possible medial patellar luxation

INTERPRETED BY

Sebastian Schaub, DVM
Dr. med. vet. DipECVDI

INTERPRETATION OF THE FINDINGS & FURTHER RECOMMENDATIONS

The degenerative joint disease of the stifle joints is more accentuated in the right stifle joint, in combination with the clinical examination and the possible cranial subluxation of the right tibia (partial)rupture of the cranial cruciate ligament ± meniscal pathology is the top diagnosis.

HOSPITAL NAME

Tenafly Vet Center

The mild degenerative changes of the left stifle joint can indicate early stage of pathology of the cranial cruciate ligament as well – check clinically for positive drawer sign/tibial compression test.

The relevance of the suspected medial patellar luxation is questionable.

REFERRING VET

Han

INVOICE

53137

DATE

7-28-22



PATIENT

Josie Finnen

SPECIES

Canine

BREED

Havanese

SEX

Spayed Female

AGE

11 Years

INTERPRETED BY

Sebastian Schaub, DVM
Dr. med. vet. DipECVDI

HOSPITAL NAME

Tenafly Vet Center

REFERRING VET

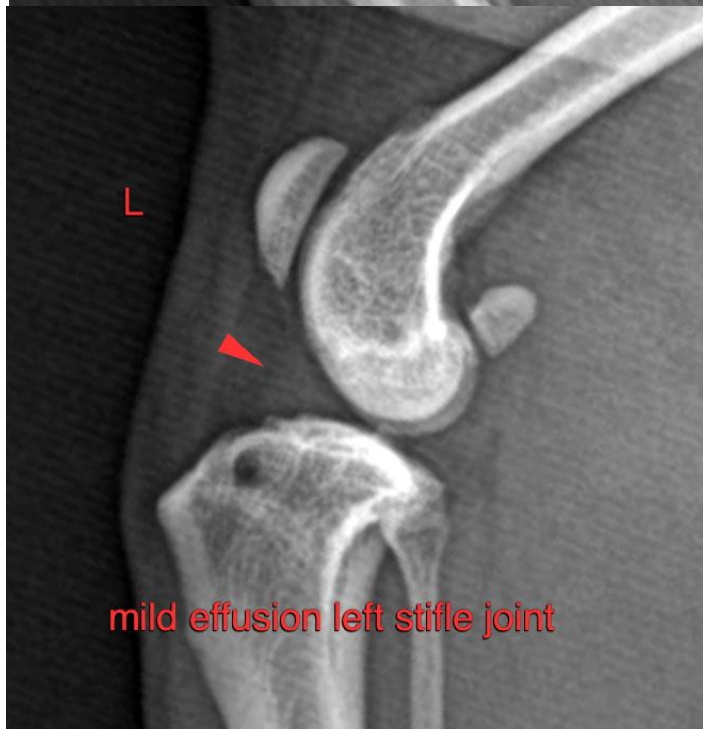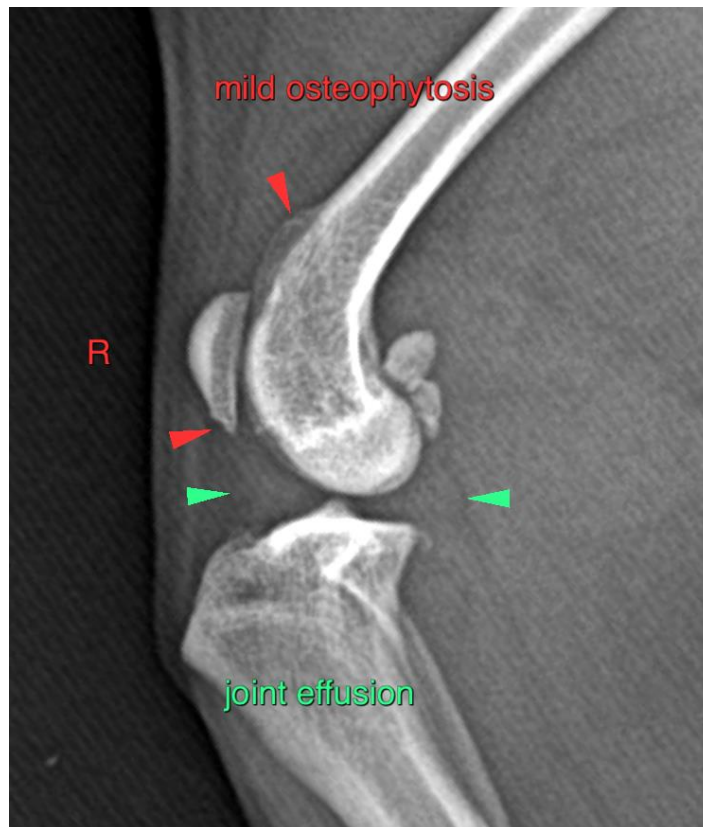
Han

INVOICE

53137

DATE

7-28-22





PATIENT

Josie Finnen

SPECIES

Canine

BREED

Havanese

SEX

Spayed Female

AGE

11 Years

INTERPRETED BY

Sebastian Schaub, DVM
Dr. med. vet. DipECVDI

HOSPITAL NAME

Tenafly Vet Center

REFERRING VET

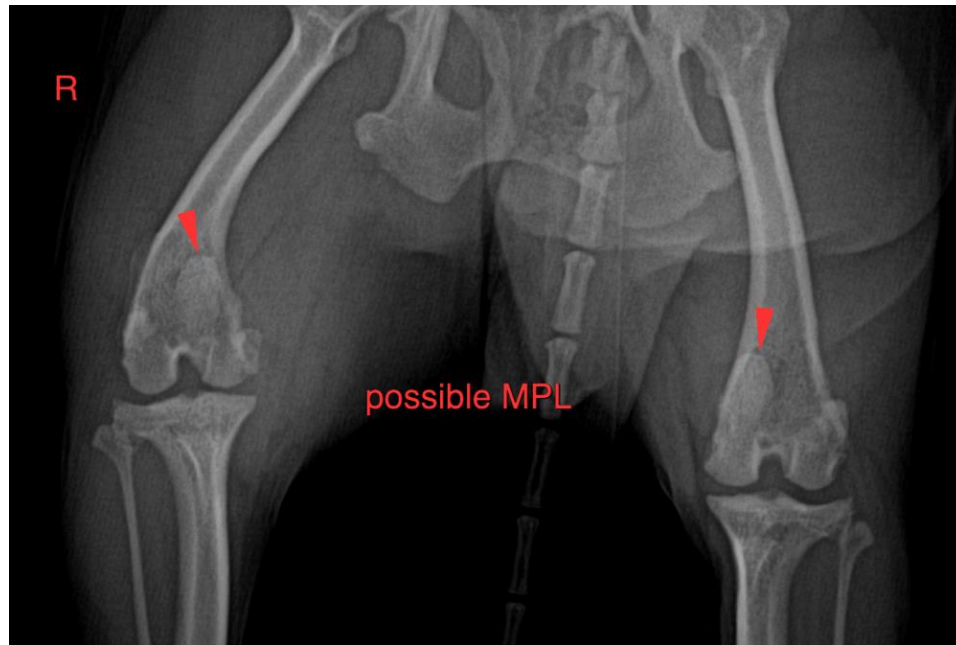
Han

INVOICE

53137

DATE

7-28-22



The information and recommendations provided are based on the images presented by the referring veterinarian/sonographer. No evaluation can be communicated regarding pathology that was not visible in the image/video clips provided.

Thank you for this referral. If the clinical or image interpretation does not parallel your findings or if I can be of any further assistance please contact me.

Sebastian Schaub, Sebastian Schaub, DVM, Dr. med. vet. DipECVDI
sebast.schaub@gmail.com