



PATIENT PRESENTING CLINICAL SIGNS

Domino Samy Tracheal sensitivity and regurgitating after drinking. Want to rule out hiatal hernia prior to soft palate surgery.

SPECIES COMPUTED TOMOGRAPHY OF THE ABDOMEN

Canine A pre- and post-contrast CT study of the abdomen in a soft tissue reconstruction is provided for review.

BREED COMPUTED TOMOGRAPHIC FINDINGS

French Bulldog In the pictured parts of the thorax, the esophagus is generalized moderately dilated by gas.

The left cranial lung lobe presents a heterogeneous significant ground glass attenuation pattern and mild decreased volume.

SEX The serosal fat presents normal attenuation behavior. There is no evidence of peritoneal effusion or peritonitis.

Female Both kidneys present within normal limits for size, shape and organ architecture. After contrast administration a bilaterally symmetric and uniform nephro- and pyelogram is noted.

AGE The adrenal glands are within normal limits for size, shape and organ architecture.

1 Year, 4 Months Both liver presents with normal shape, even surface, uniformly attenuating parenchyma and homogeneous contrast enhancement, unremarkable.

INTERPRETED BY The pancreas is evenly contoured, the pancreatic parenchyma is homogeneous and presents uniform contrast enhancement.

Sebastian Schaub, DVM
Dr. med. vet. DipECVDI

The cardia of the stomach is in a relative cranial position, level with the esophageal hiatus of the diaphragm. The esophageal wall is subjectively generalized mildly thickened. The position, delineation, wall and content of the gastrointestinal tract are considered within normal limits throughout.

HOSPITAL NAME The thoracic spine presents with multiple hemivertebra.

Adelaide Plains
Veterinary Surgery

COMPUTED TOMOGRAPHIC DIAGNOSIS

- REFERRING VET**
- Relative cranial position of the cardia, level with the esophageal hiatus of the diaphragm
 - Suspect generalized mild mural thickening of the esophageal wall
 - Generalized esophageal dilation
 - Marked unstructured interstitial pattern left cranial lung lobe

John Katakasi

INVOICE INTERPRETATION OF THE FINDINGS & FURTHER RECOMMENDATIONS

53139 The relative cranial position of the cardia of the stomach can be caused by relaxation of the diaphragm due to anesthesia. No part of the stomach is extending cranially beyond the level of the stomach, which would indicate sliding hiatal hernia.

DATE The generalized dilation of the esophagus is considered as a sequela to general anesthesia. However, in combination with the subjective prominent wall of the esophagus, esophagitis ± esophageal dysmotility is a likely differential here.

7-28-22

At this point consider management of brachycephalic airway syndrome including aggressive



PATIENT

Domino Sammy

gastric protection therapy. If clinical signs are refractory to management radiographs centered on the diaphragm with pressure applied on the abdomen can be used to check for sliding hiatal hernia.

SPECIES

Canine

The pattern of the left cranial lung lobe can be a sequela to dystelectasis due to general anesthesia, however as the volume is only mildly decreased pneumonia needs to be considered as well. Recommend blood work to screen for inflammatory changes.

BREED

French Bulldog

SEX

Female

AGE

1 Year, 4 Months

INTERPRETED BY

Sebastian Schaub, DVM
Dr. med. vet. DipECVDI

HOSPITAL NAME

Adelaide Plains
Veterinary Surgery

REFERRING VET

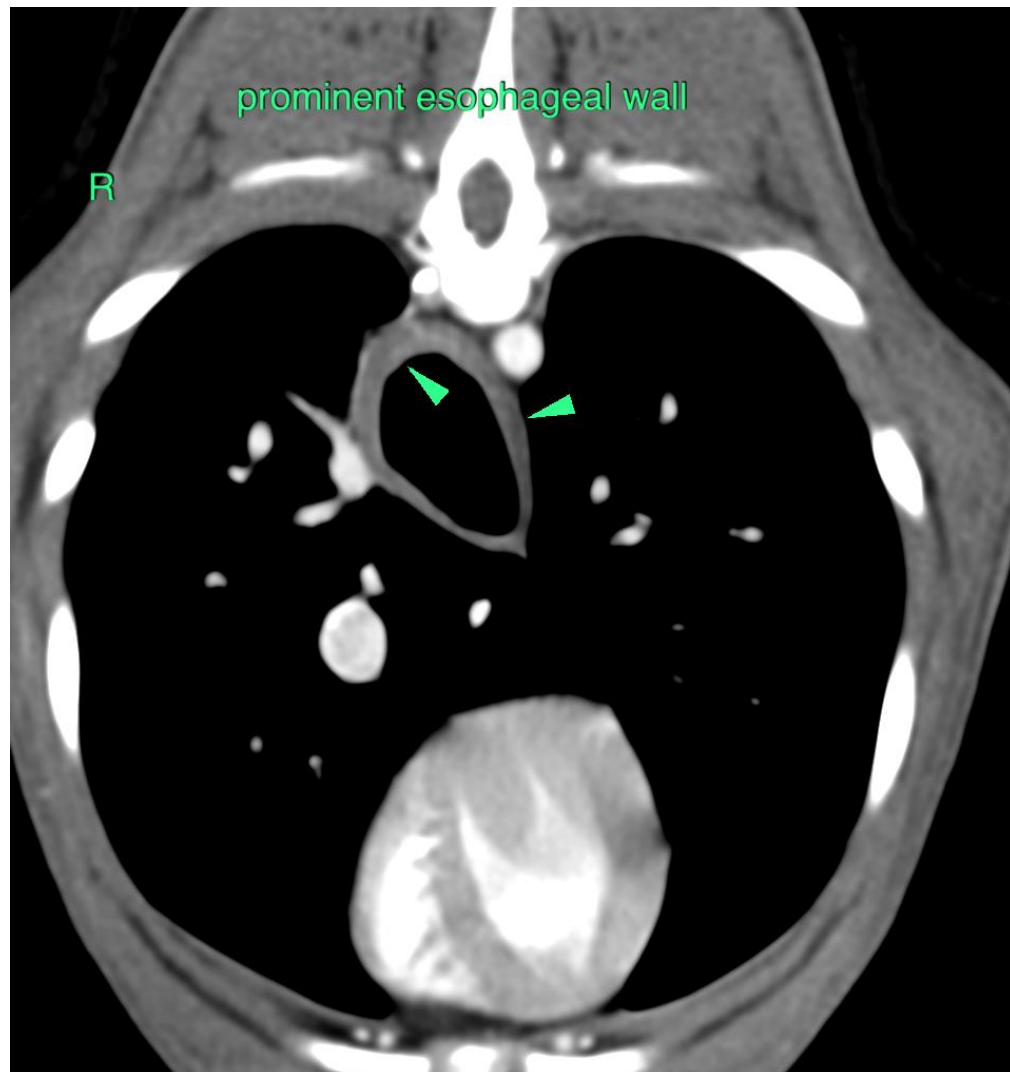John Katakasi

INVOICE

53139

DATE

7-28-22





PATIENT

Domino Samy

SPECIES

Canine

BREED

French Bulldog

SEX

Female

AGE

1 Year, 4 Months

INTERPRETED BY

Sebastian Schaub, DVM
Dr. med. vet. DipECVDI

HOSPITAL NAME

Adelaide Plains
Veterinary Surgery

REFERRING VET

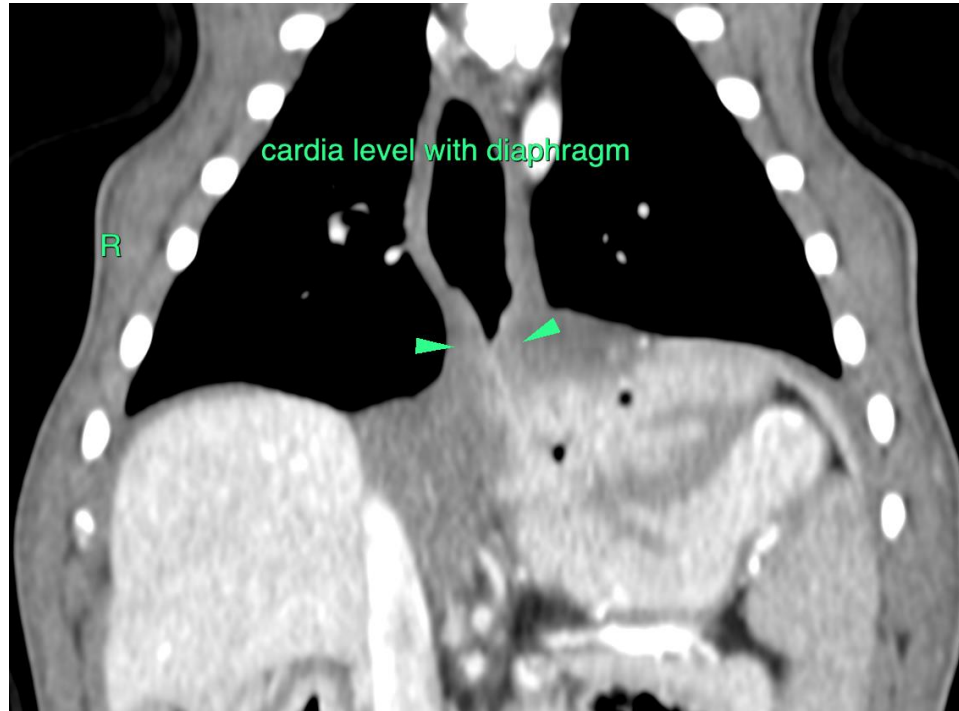
John Katakasi

INVOICE

53139

DATE

7-28-22



The information and recommendations provided are based on the images presented by the referring veterinarian/sonographer. No evaluation can be communicated regarding pathology that was not visible in the image/video clips provided.

Thank you for this referral. If the clinical or image interpretation does not parallel your findings or if I can be of any further assistance please contact me.

Sebastian Schaub, Sebastian Schaub, DVM, Dr. med. vet. DipECVDI
sebast.schaub@gmail.com